



7TH Advanced Course on Knee Surgery
14th to 18th January 2018
Val d'Isère – France

ORIF-How I do (Stable/Unstable, graft or not)

Mike Carmont

Princess Royal Hospital

Shropshire, UK



More Scottish foods



Grading

- Arthroscopic
- 1 Fully intact articular cartilage
- 2 Early **articular cartilage separation**
- 3 **Partial attachment**
- 4 Crater lesion with loose body
- MRI T2
- 1 Signal change no clear margin
- 2 Osteochondral fragment clear margin no fluid
- 3 **Fluid partially visible** between fragment & bone
- 4 **Fluid completely surrounds** fragment
- Fragment detached & displaced

Ewing JW & Voto SJ. The arthroscopic surgical management of Osteochondritis Dissecans of the knee. Arthroscopy 1988;4(1):37-40

Heywood (Ax 2011) recommends MRI not used isolation

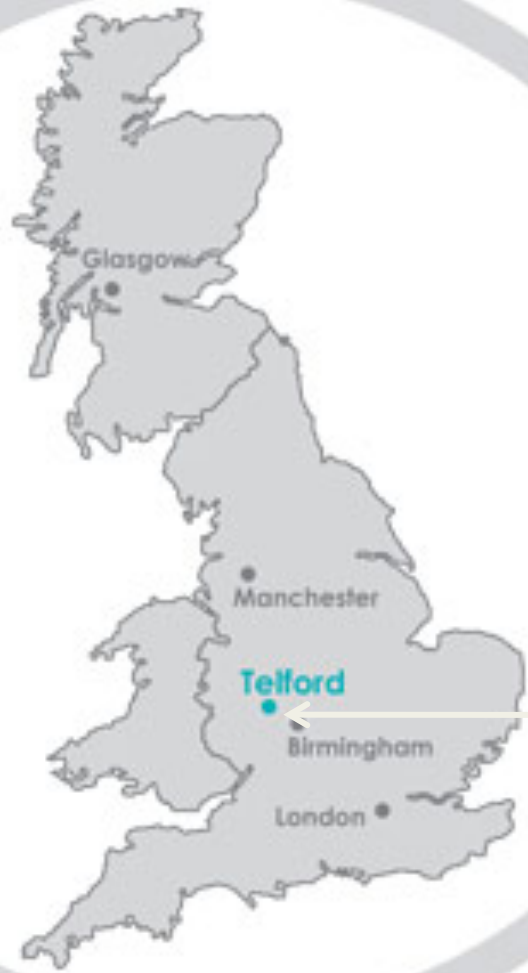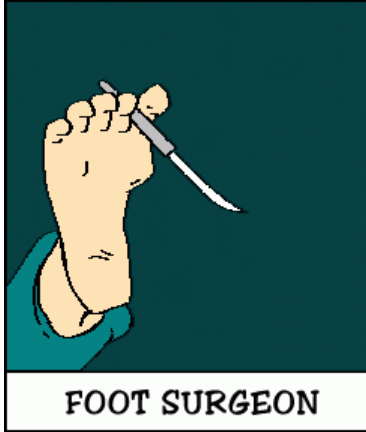
Presence sclerotic rim poor prognostic indicator (Ramirez JPO 2010)

Treatment Options

- Operative Arthroscopic/Open
 - Debridement
 - Drilling
 - Retrograde
 - Antegrade extra-articular
 - Fixation Unstable/Loose fragments?
 - Depends local kit
 - Own autograft
 - Osteochondral plug/Mosaicplasty
 - Bulk osteochondral graft

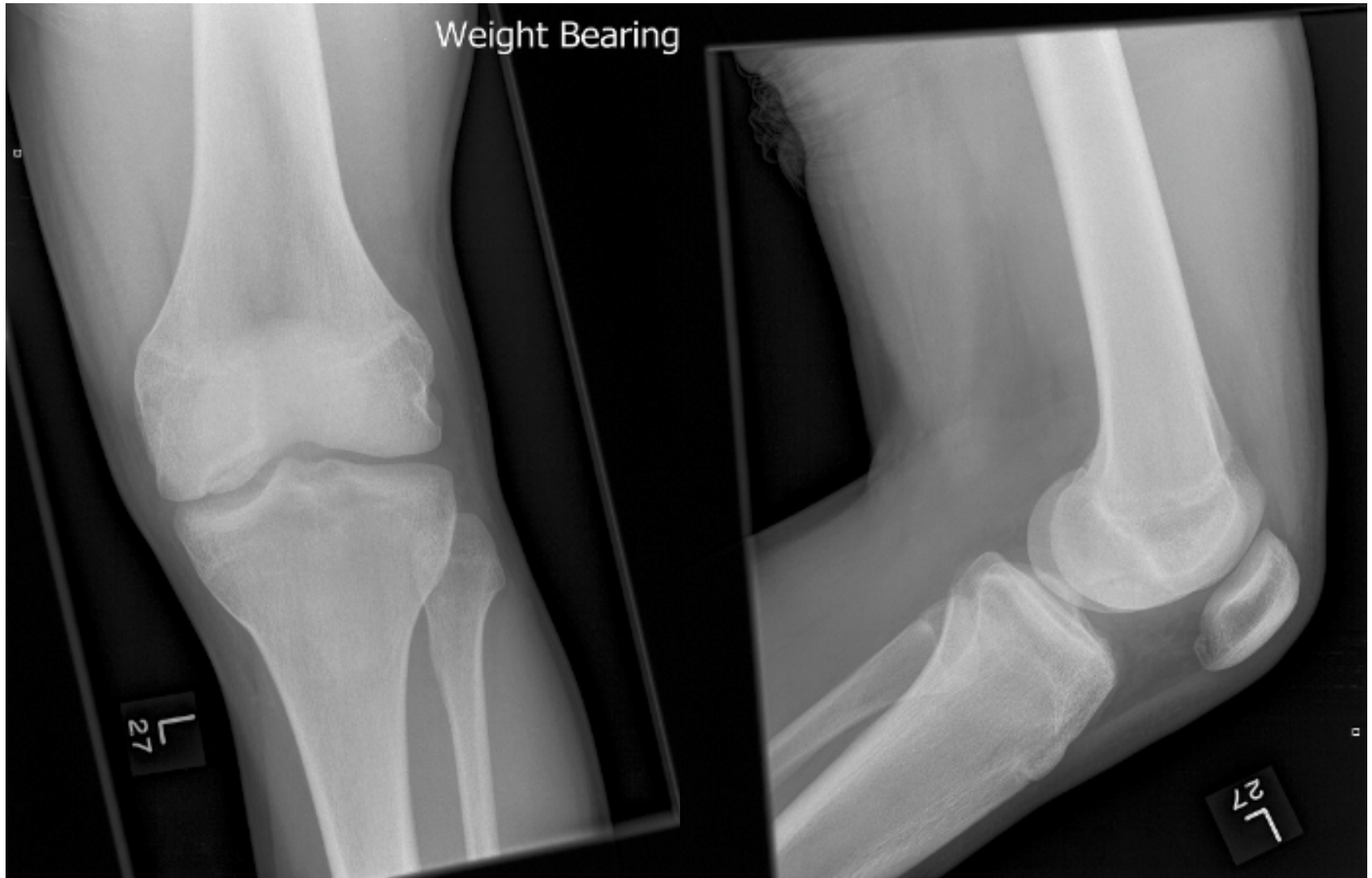

Where is Telford?

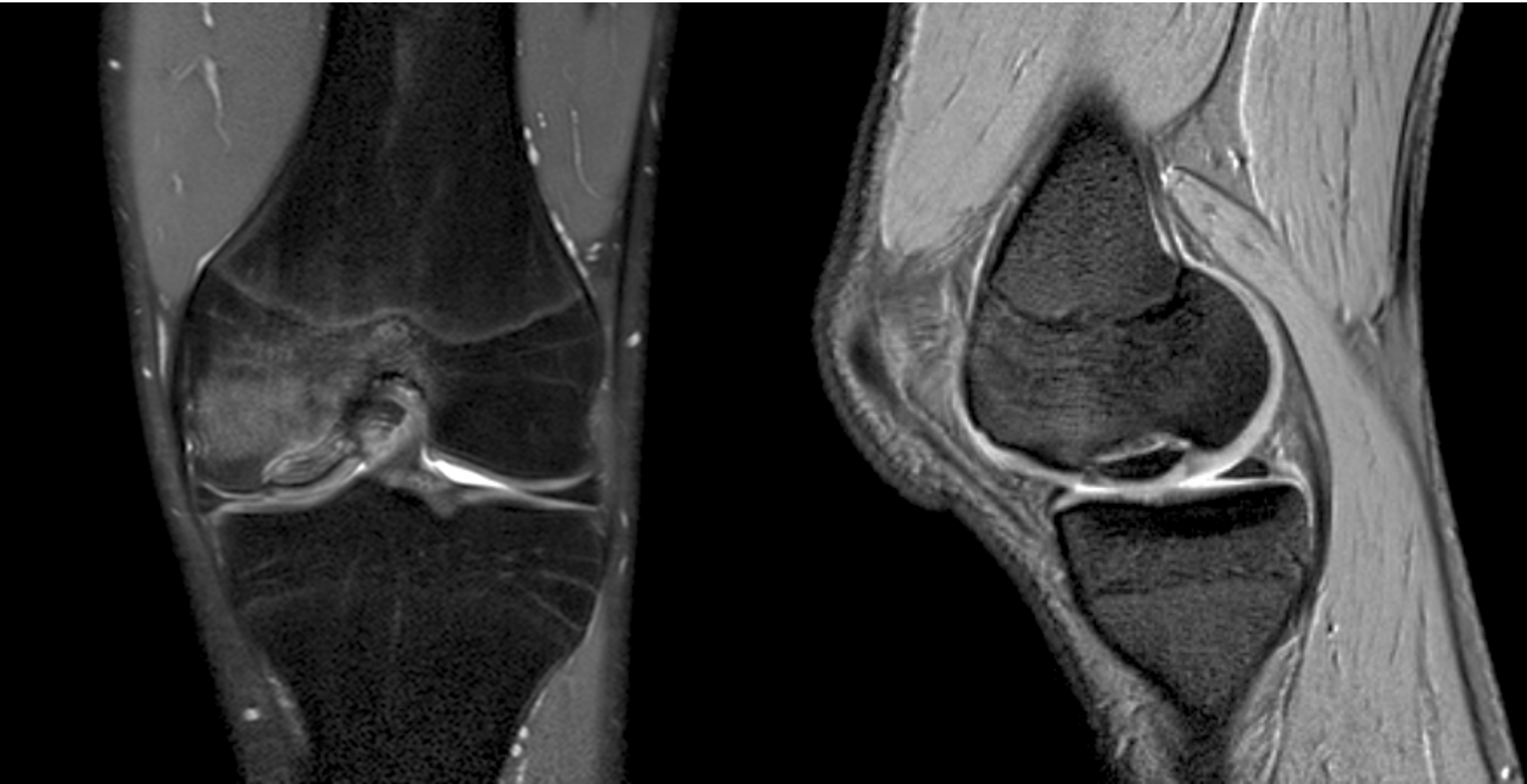

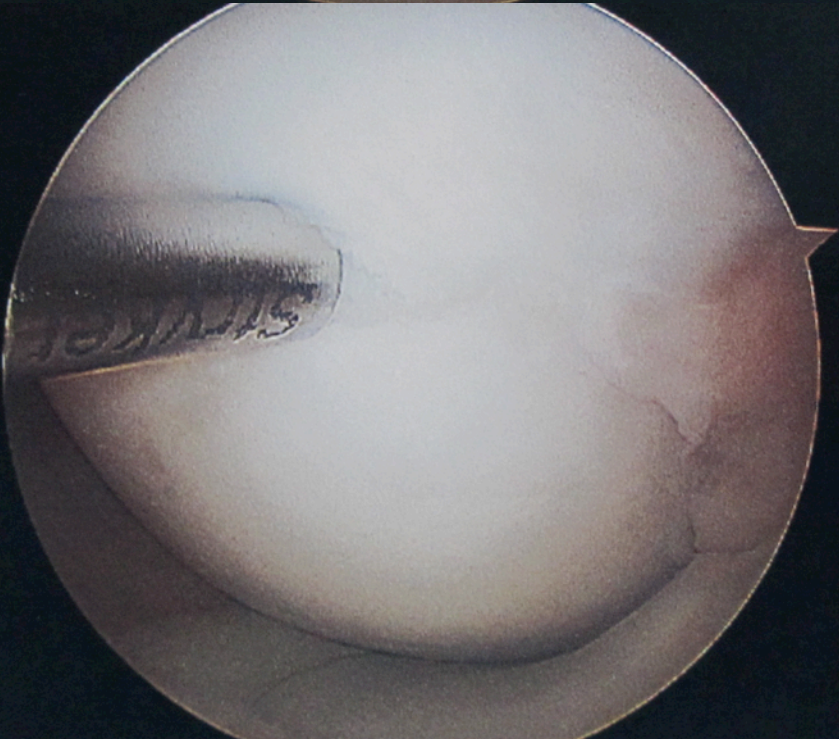
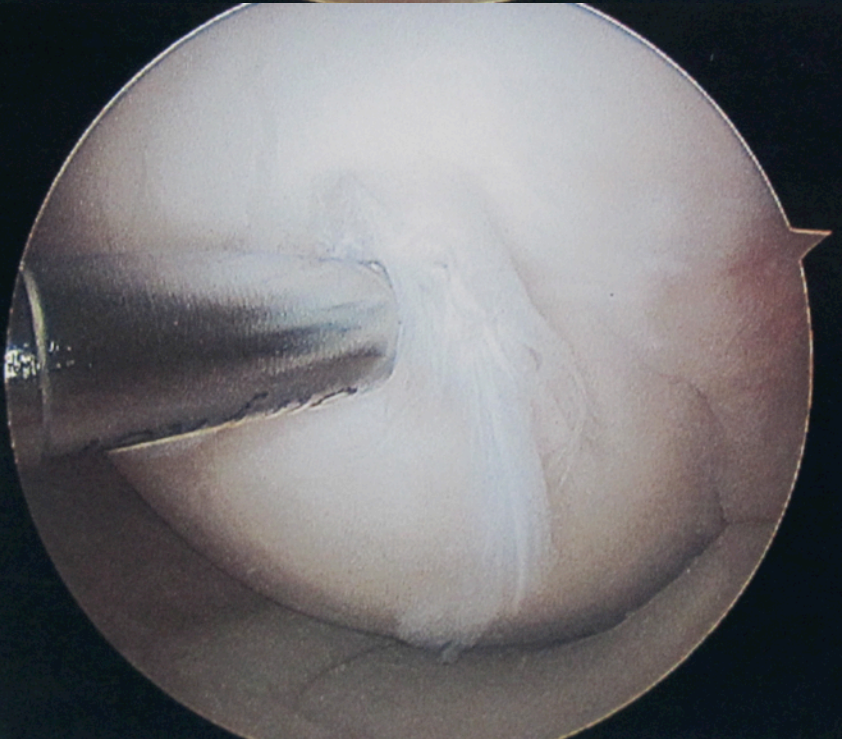
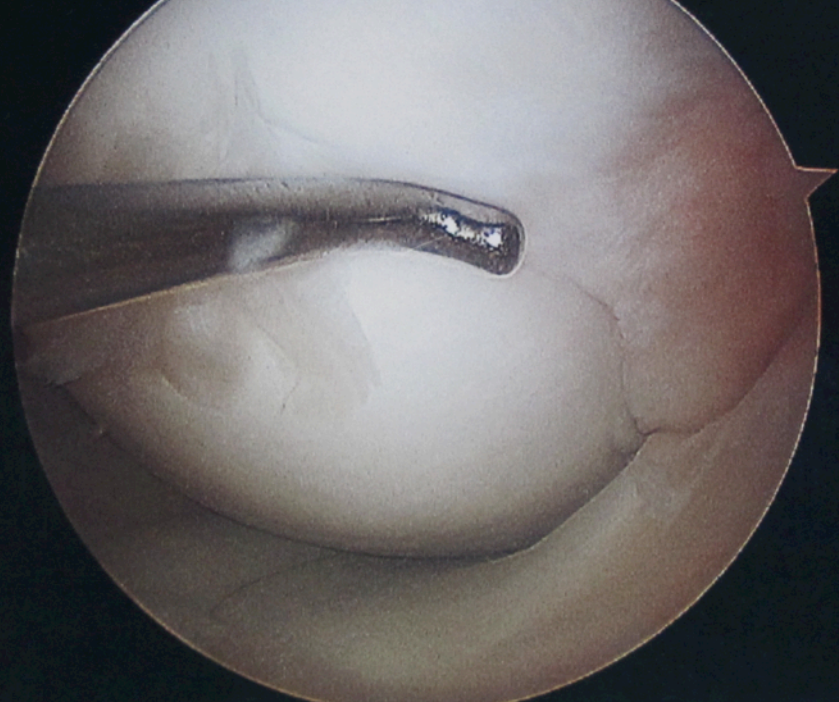
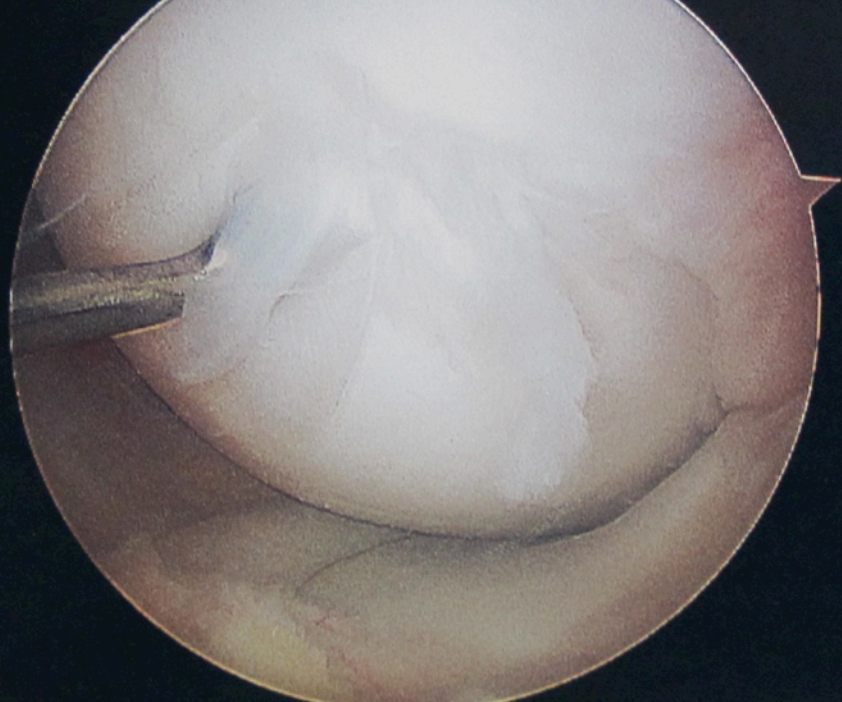
Case 1 Acute knee injury, no
noise, inability to straighten
knee,
no previous history knee injury
17yo, Young Farmer

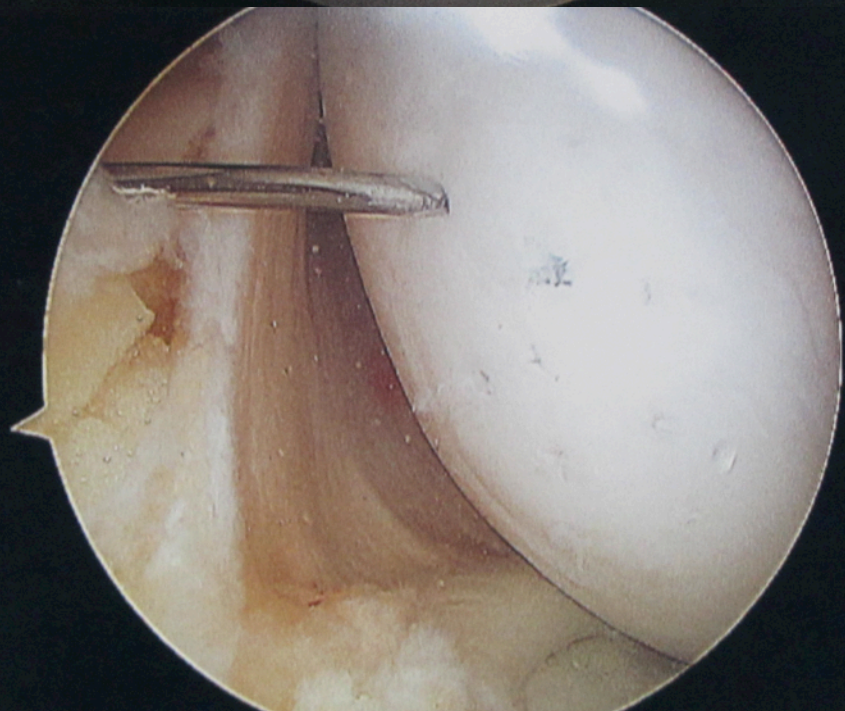
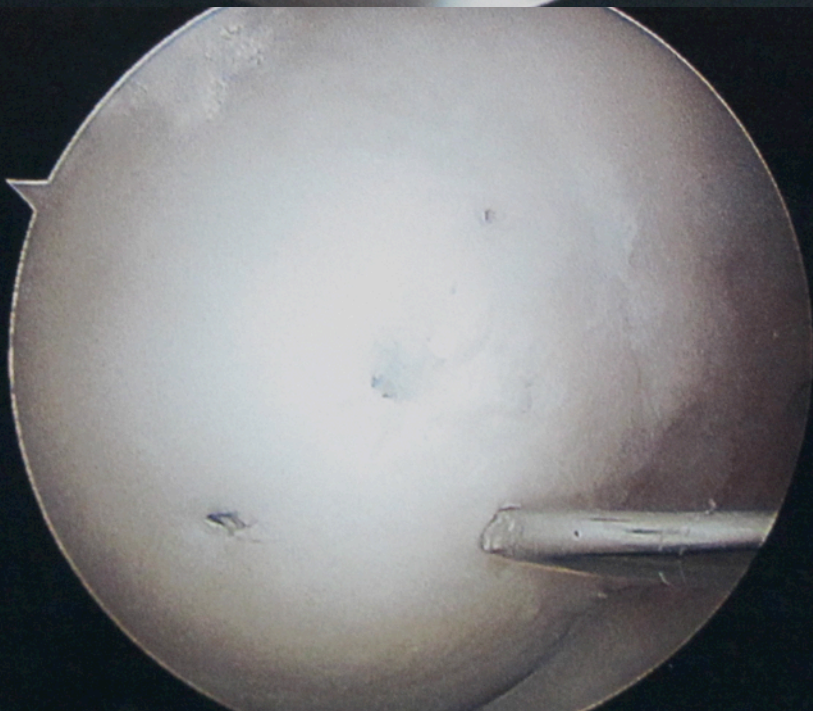
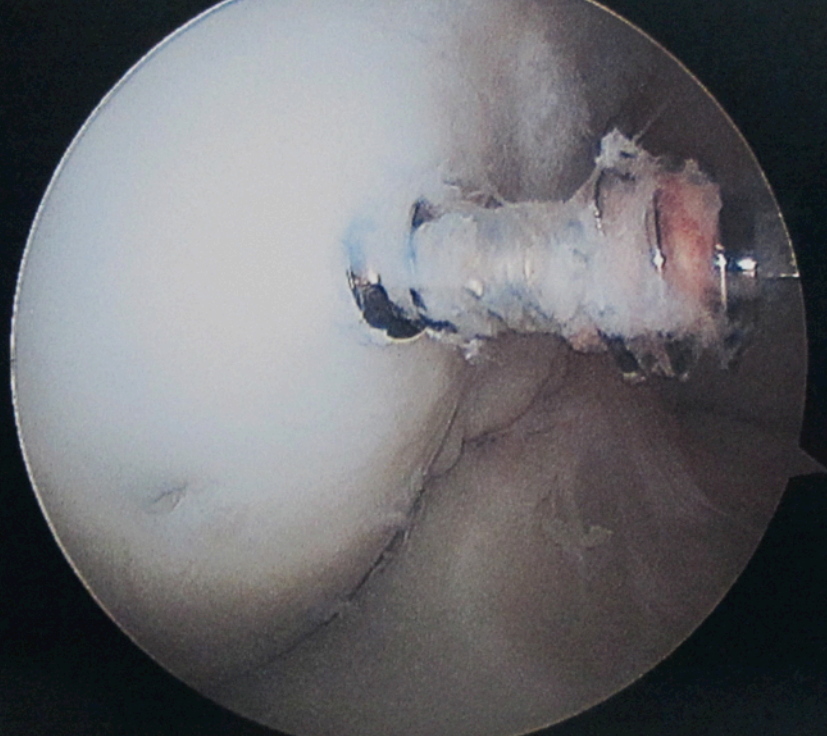
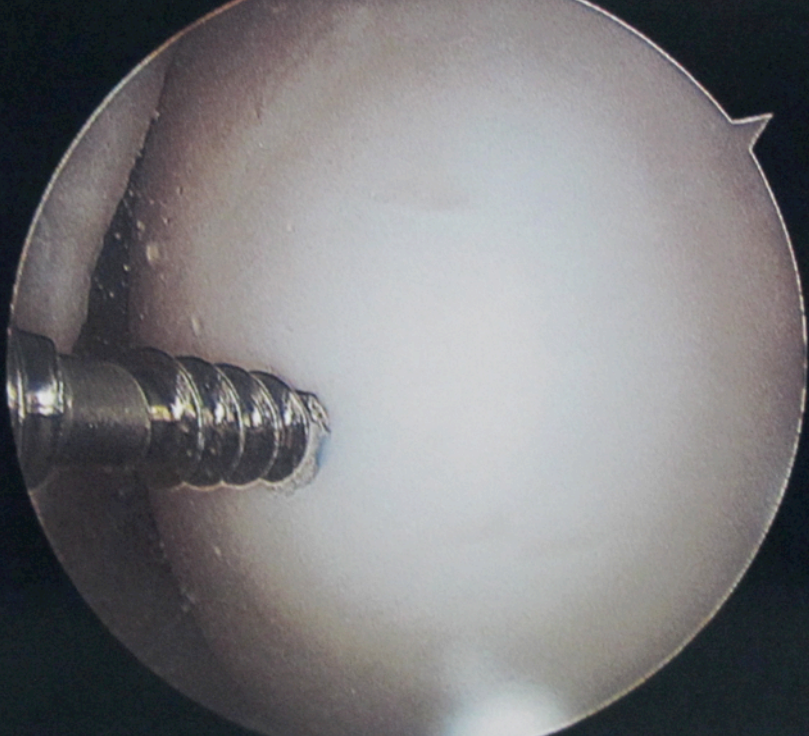
Radiographs ? undisplaced

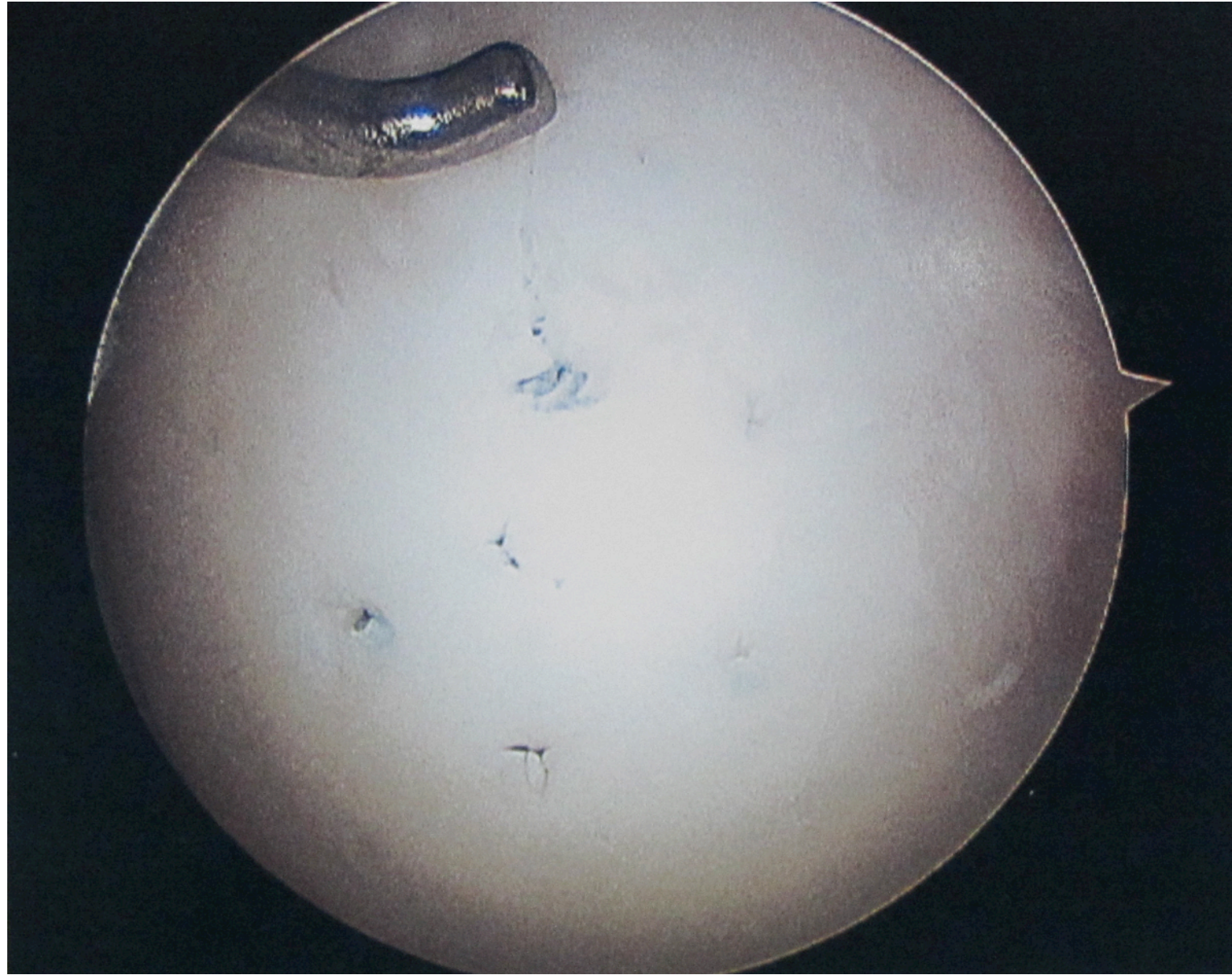


Unstable Complete fluid

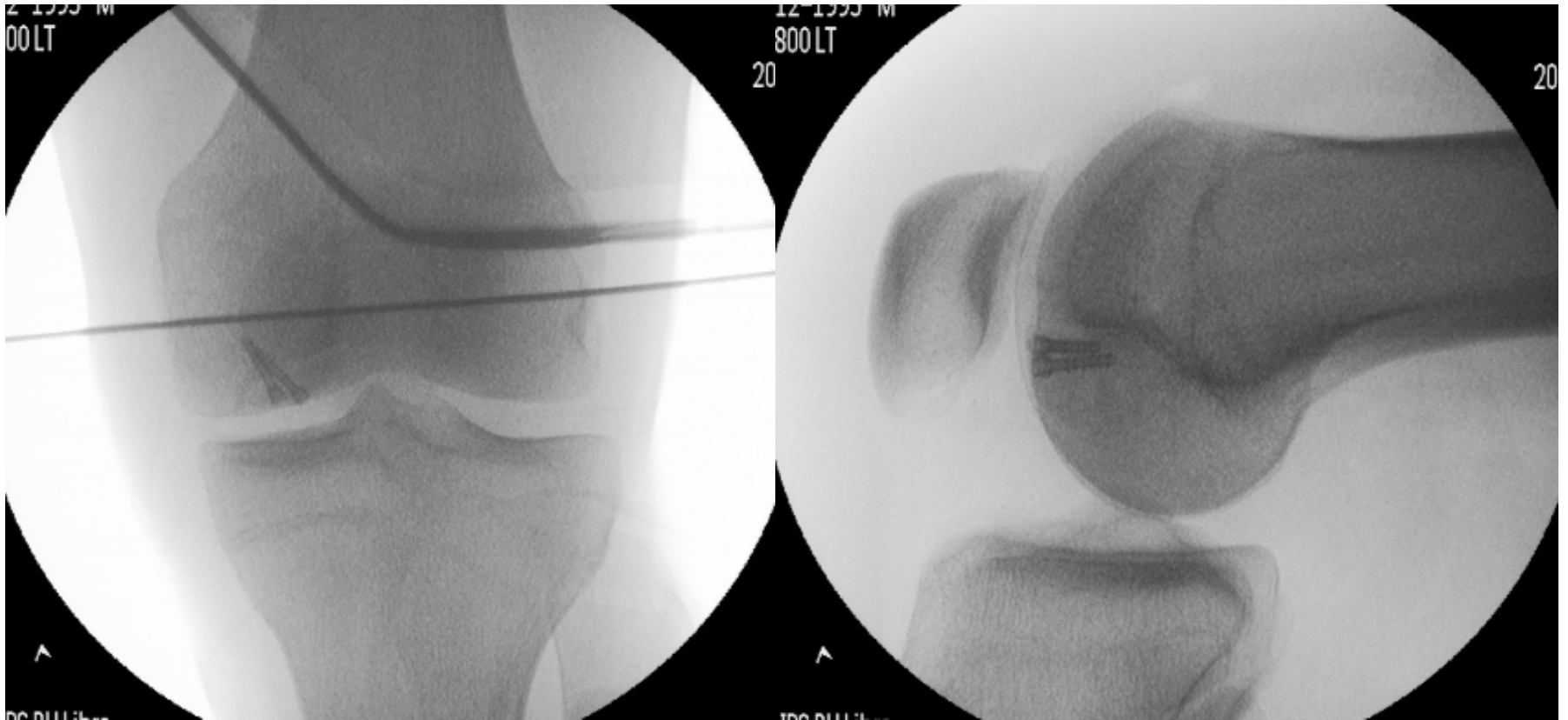




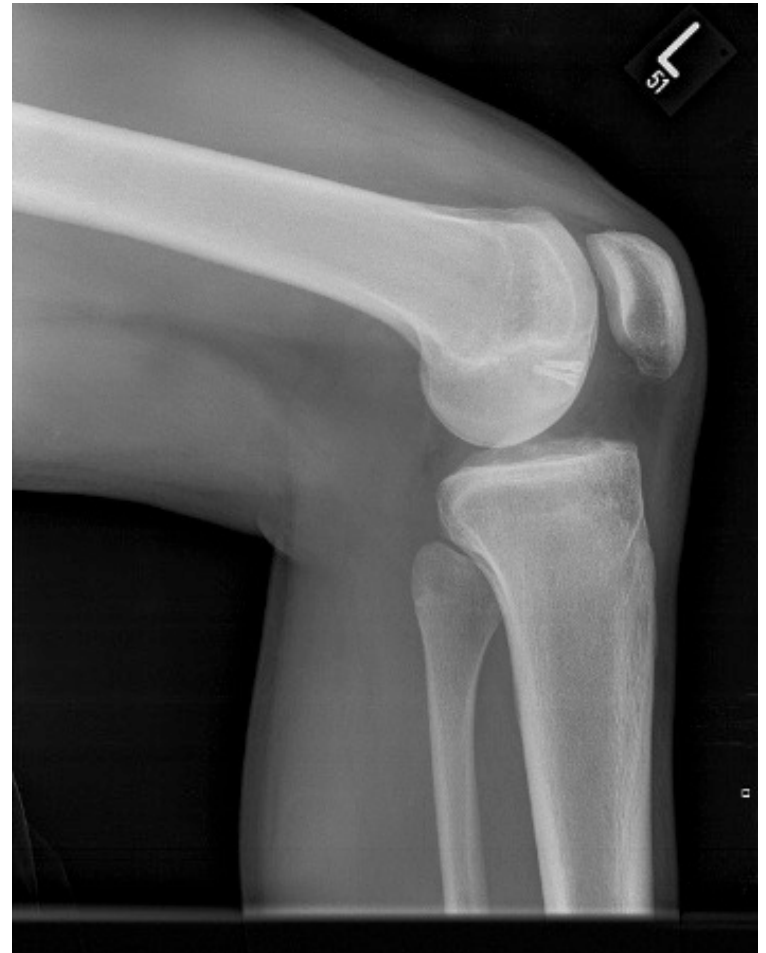
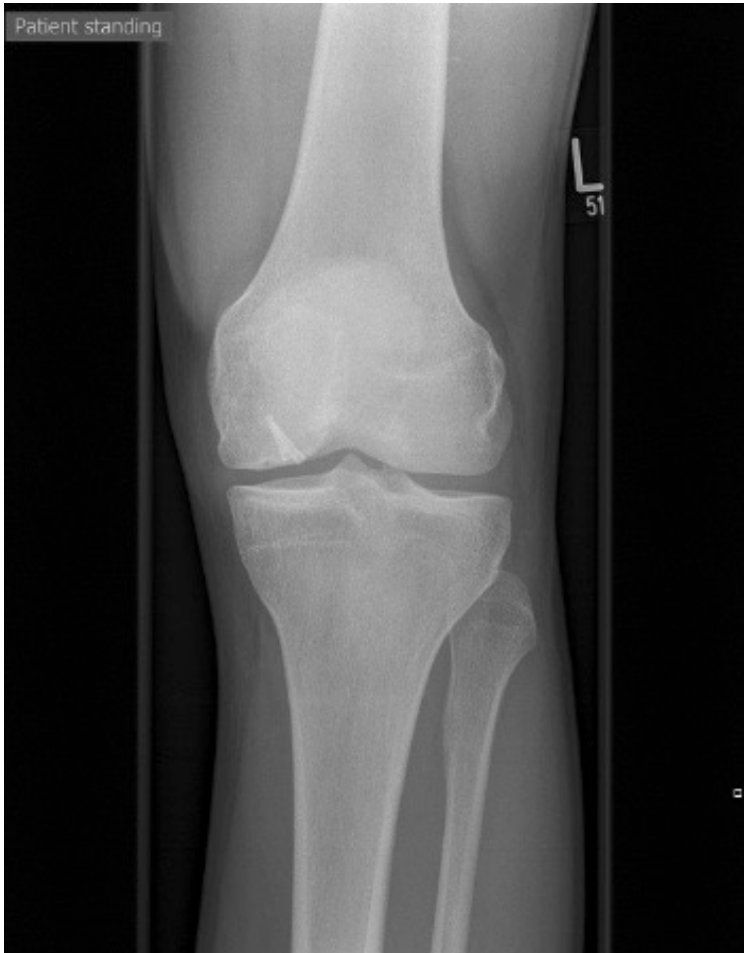


Fluoroscopy

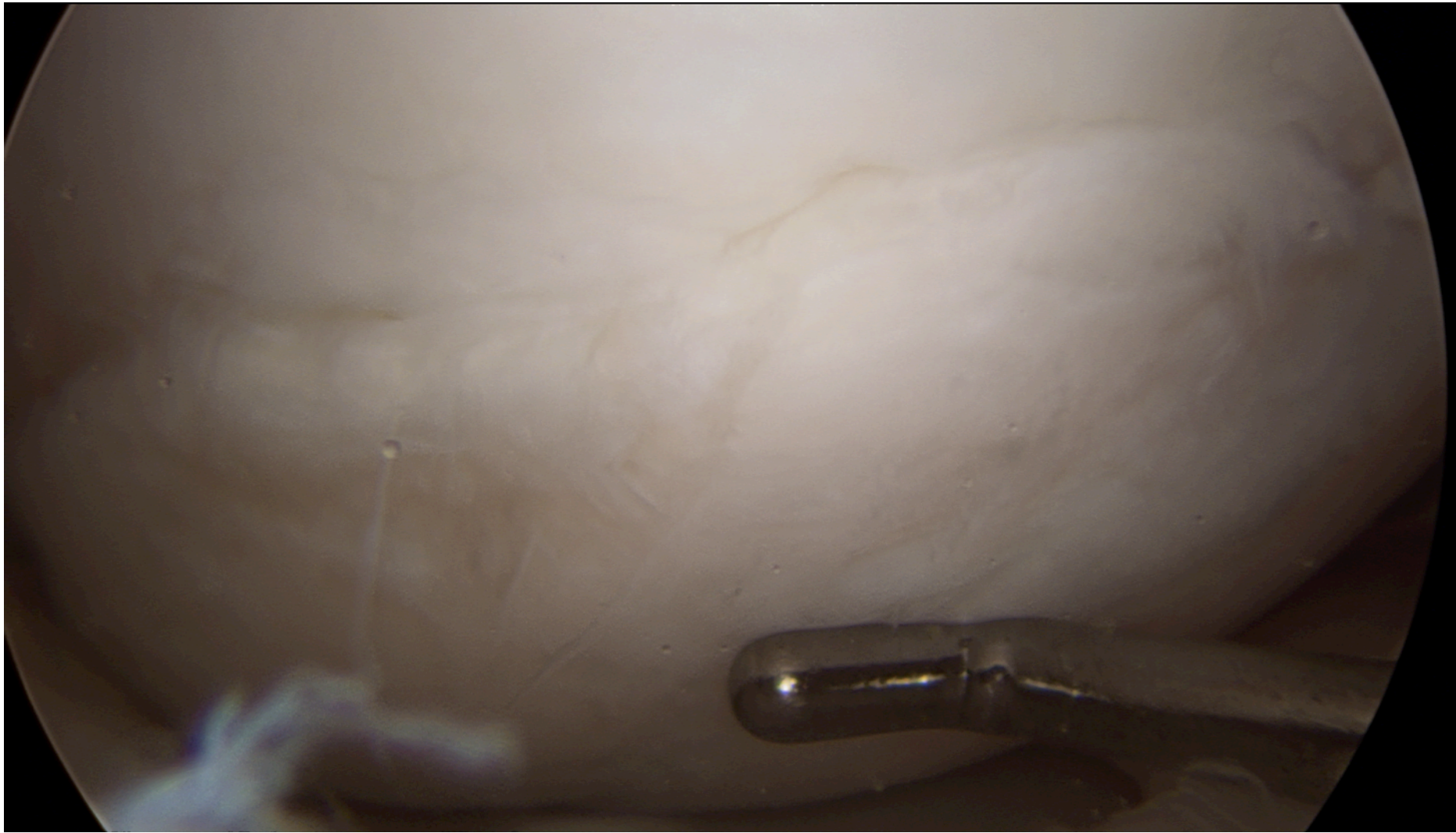


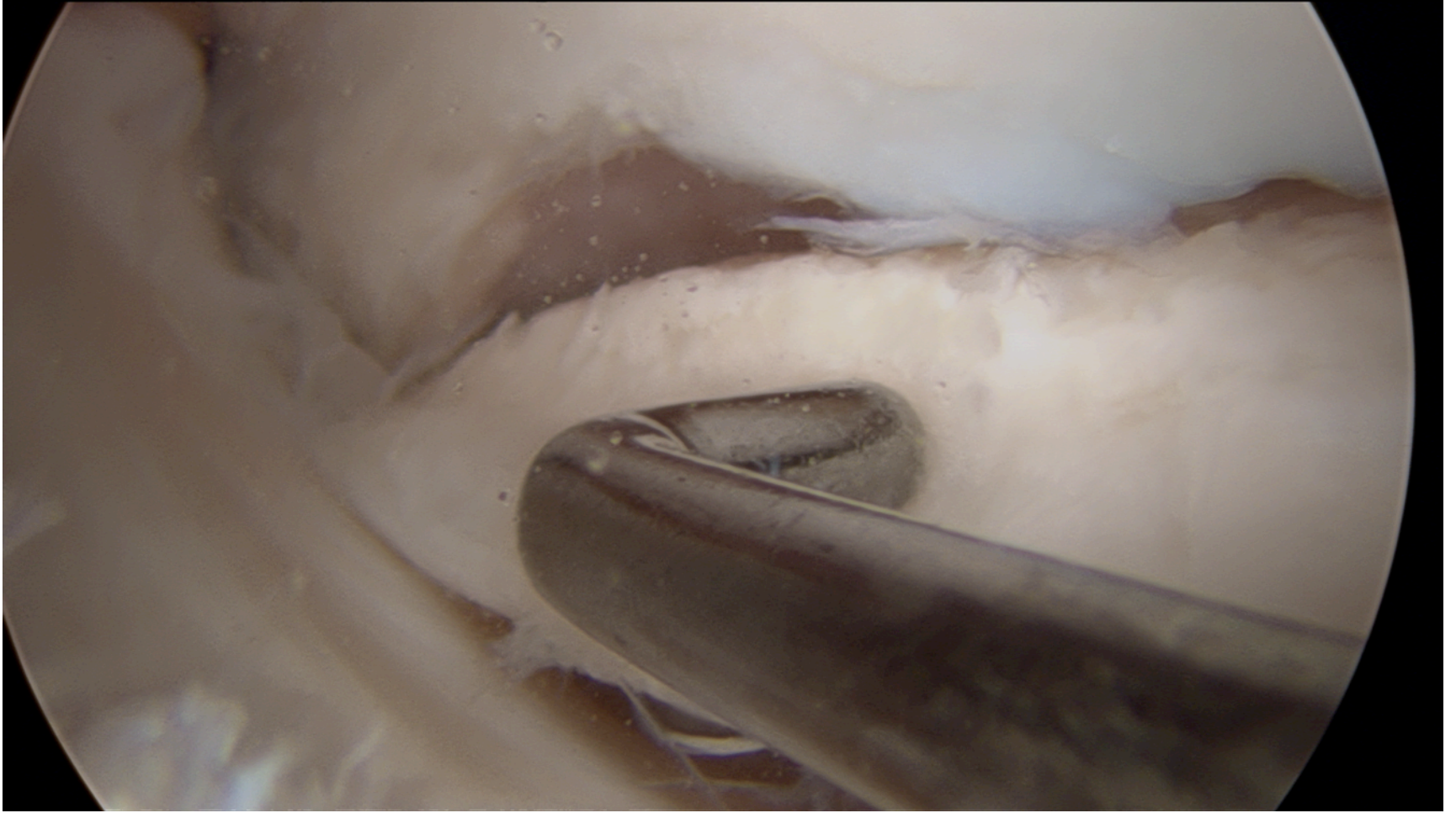
By 6 months



Case 2 29yo Primary school teacher

Hx of medial pain & clicking in the knee



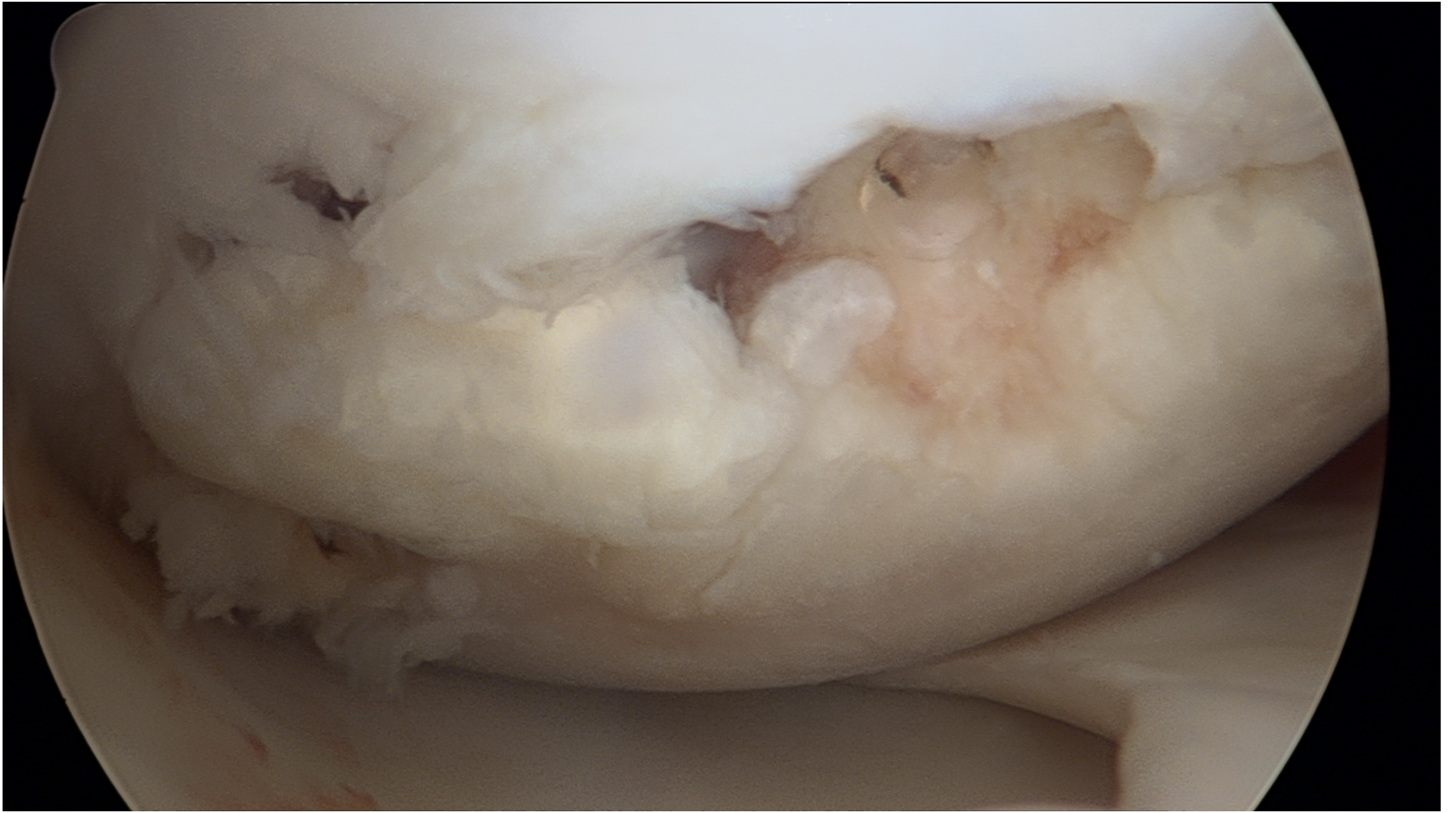


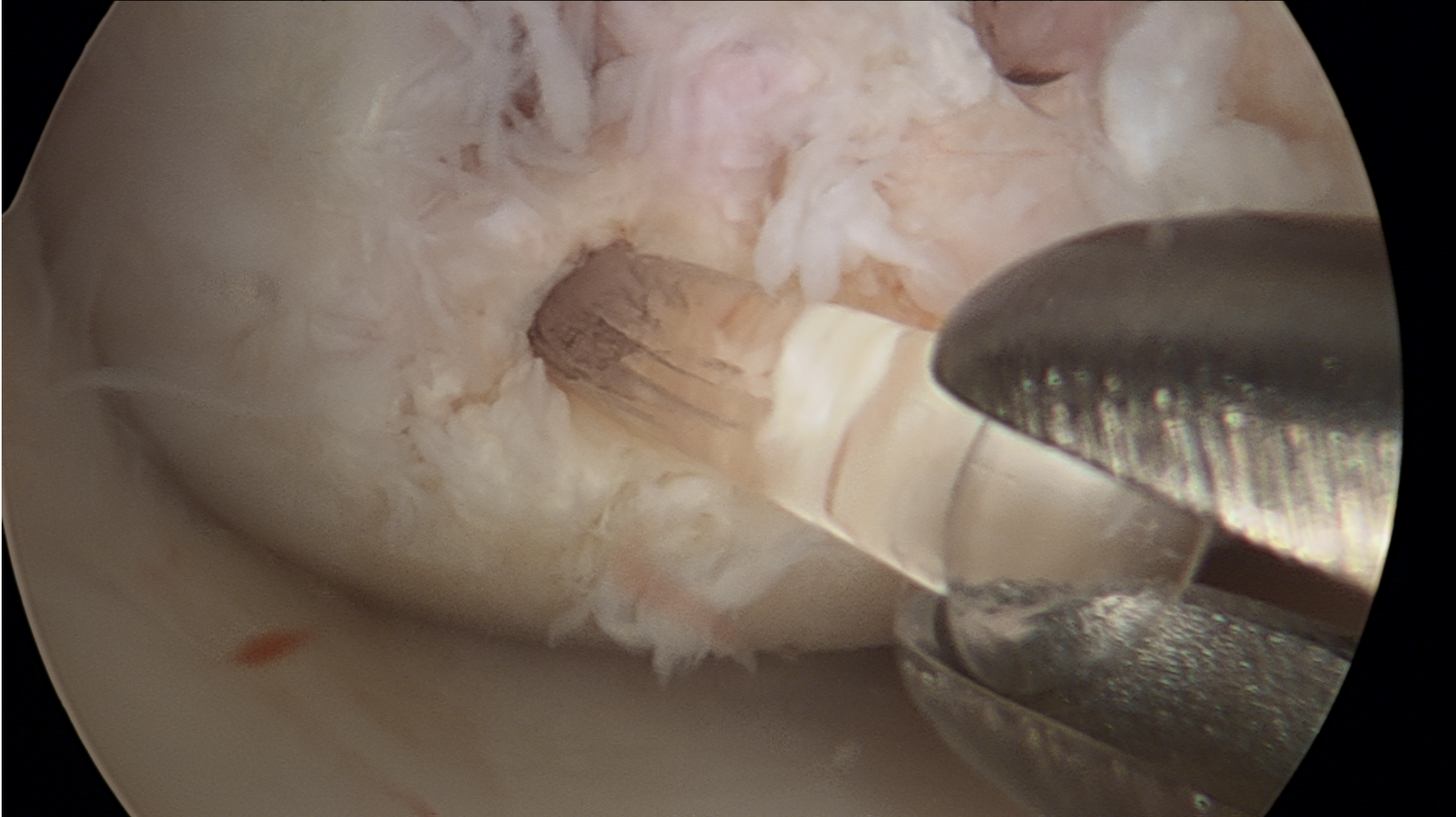3 x SMART Nails inserted & perforations

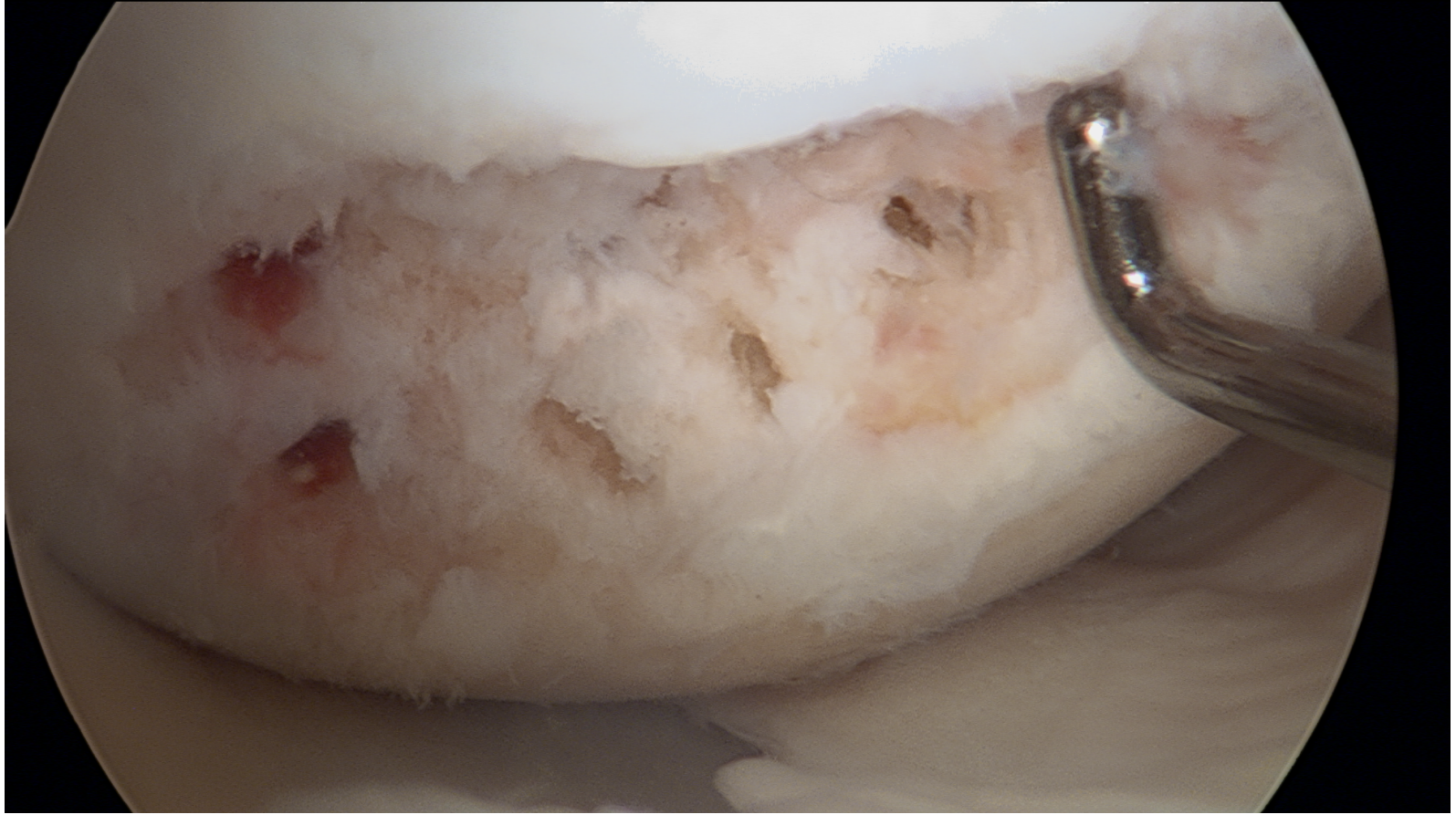


Post op

- 6/52 NWB free ROM in brace
- On going pain, effusion & synovitis







Bioabsorbable Fixation of Unstable Osteochondritis Dissecans Lesions

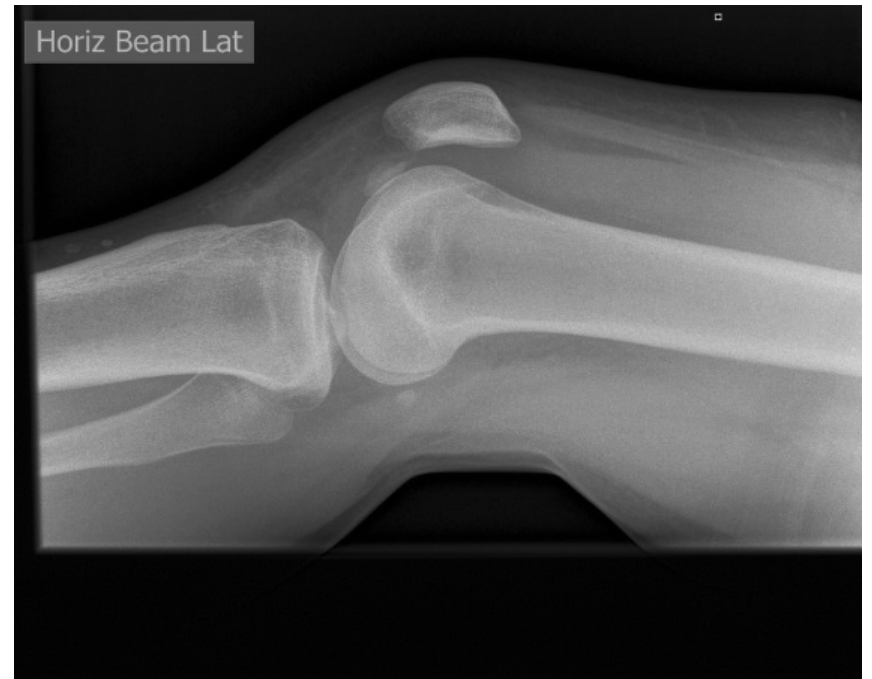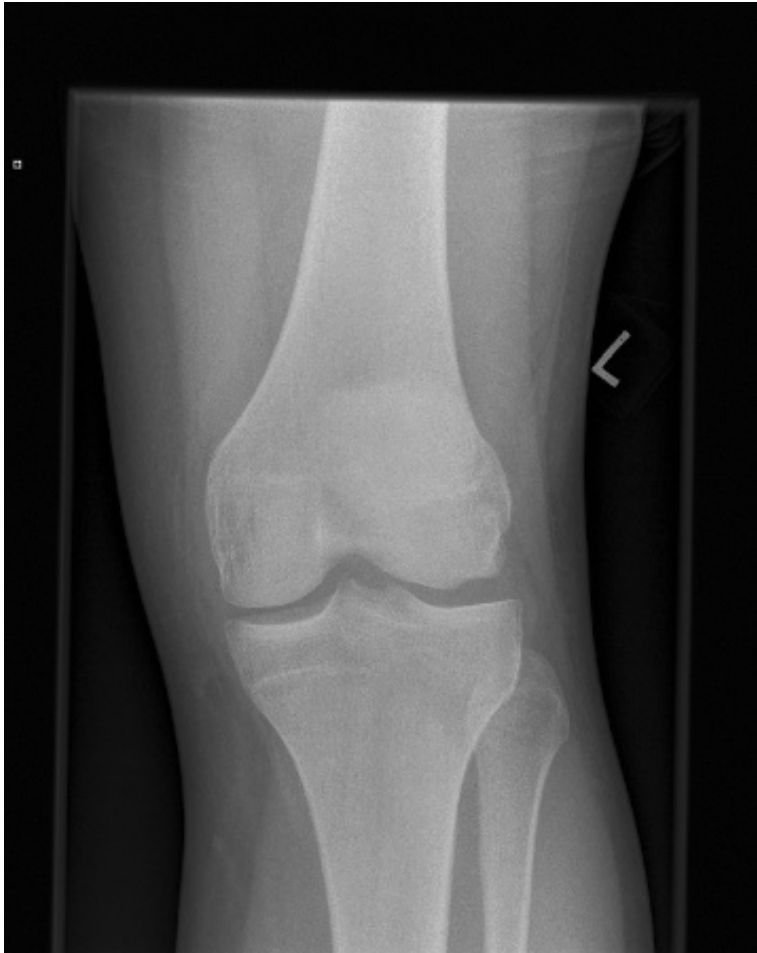Kendra L. Millington, Jay P. Shah, MD, Diane L. Dahm, MD, Bruce A. Levy, MD, and Michael J. Stuart,* MD

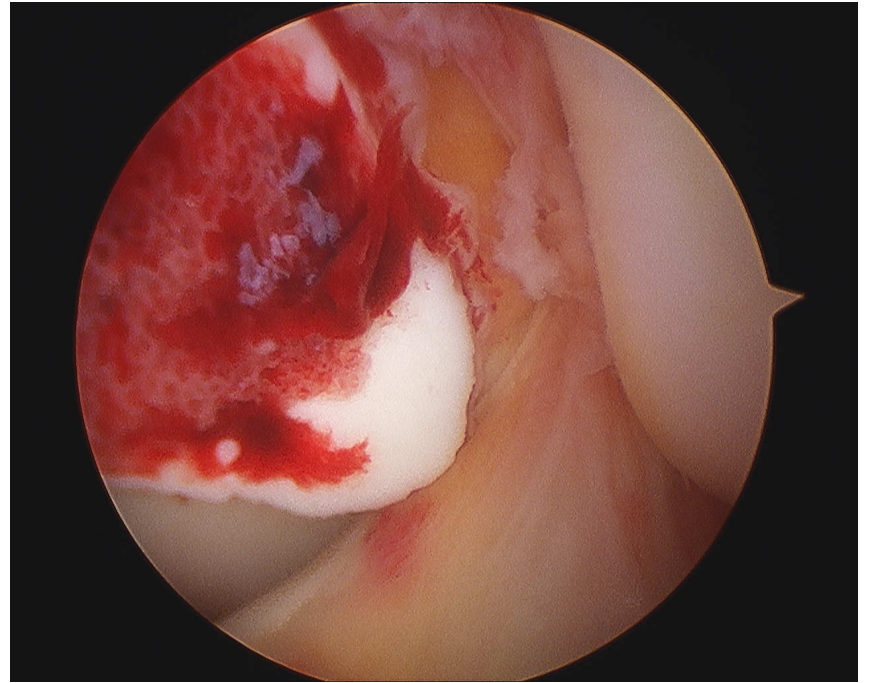
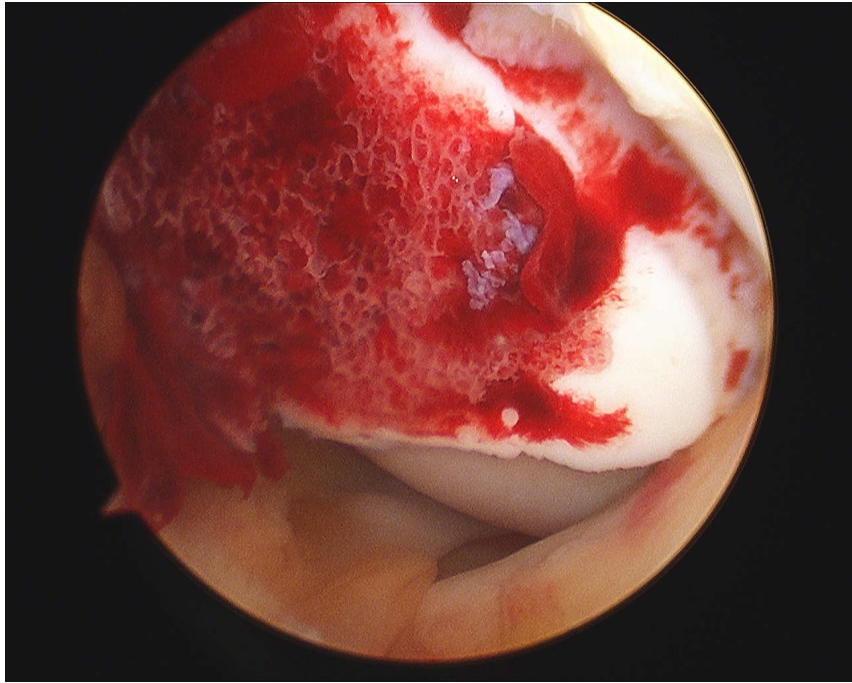
From the Mayo Clinic, Rochester, Minnesota

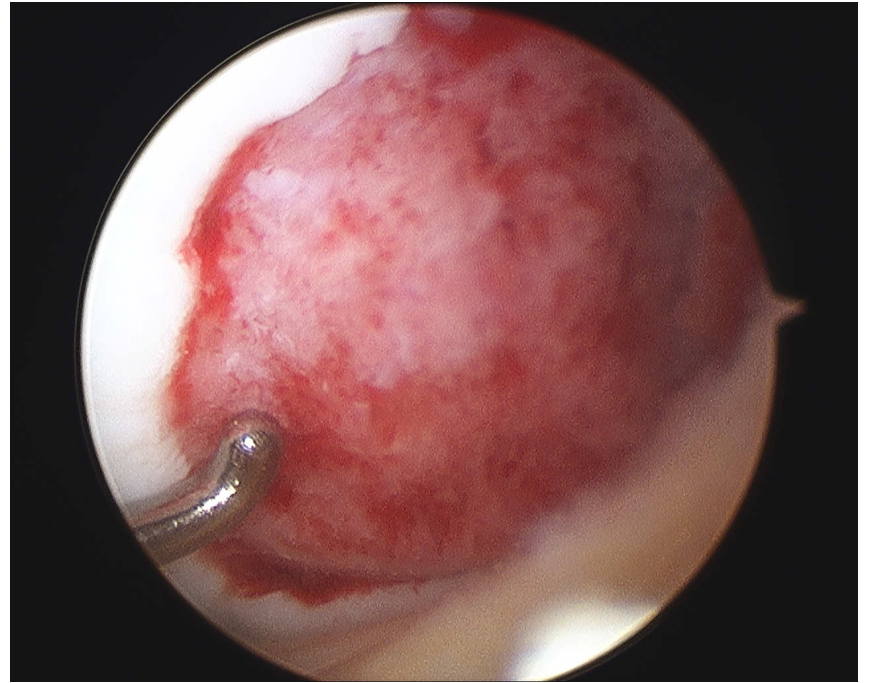
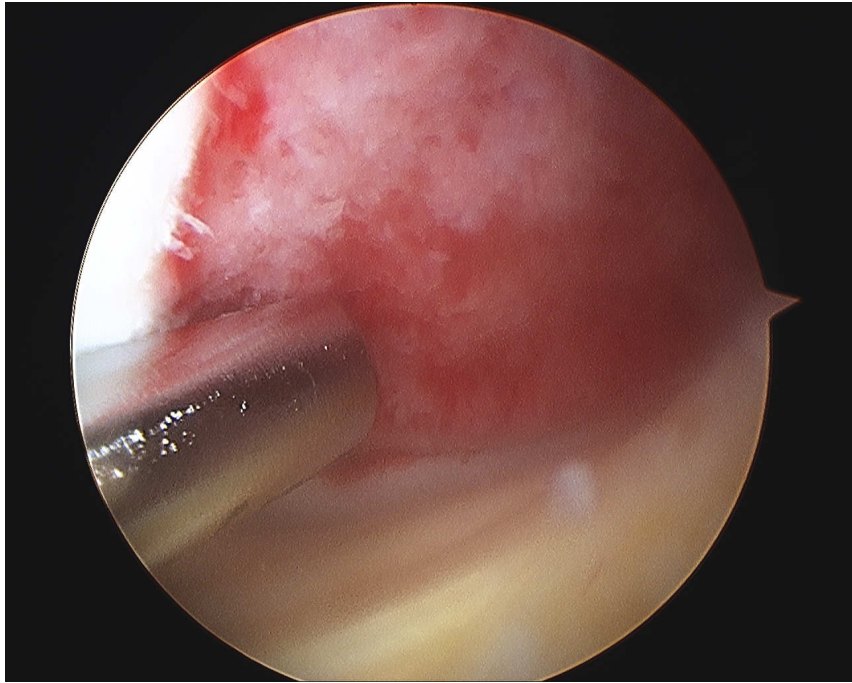
- AJSM
- Case series 18 patients
- Smartnails & pins
- Evaluated 59/12
 - Union 67%
 - Removed 33%
 - Nail back out 18%

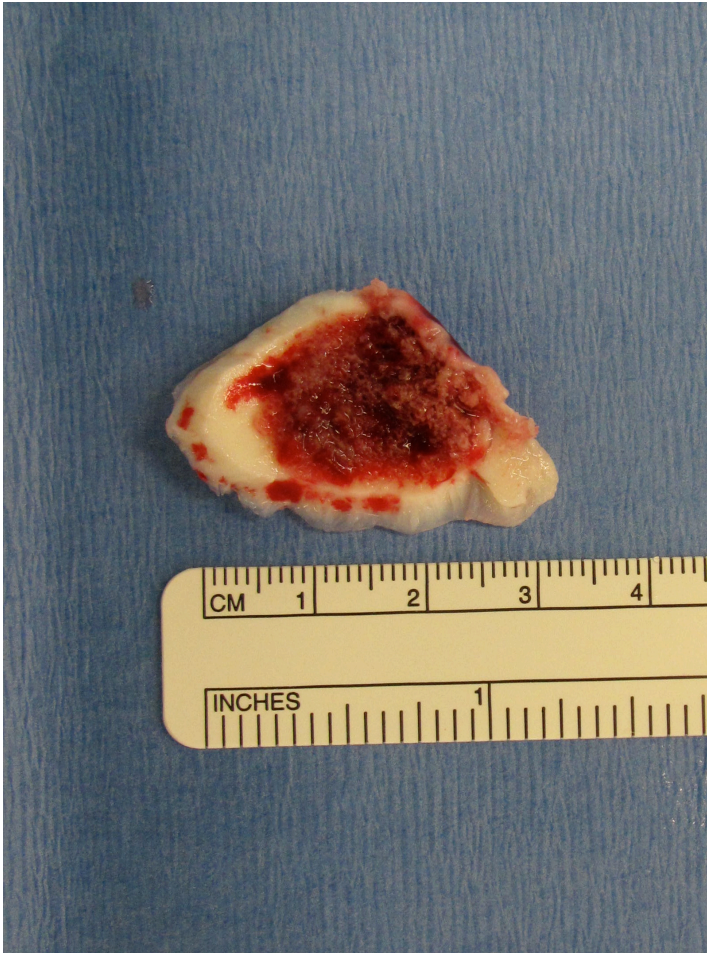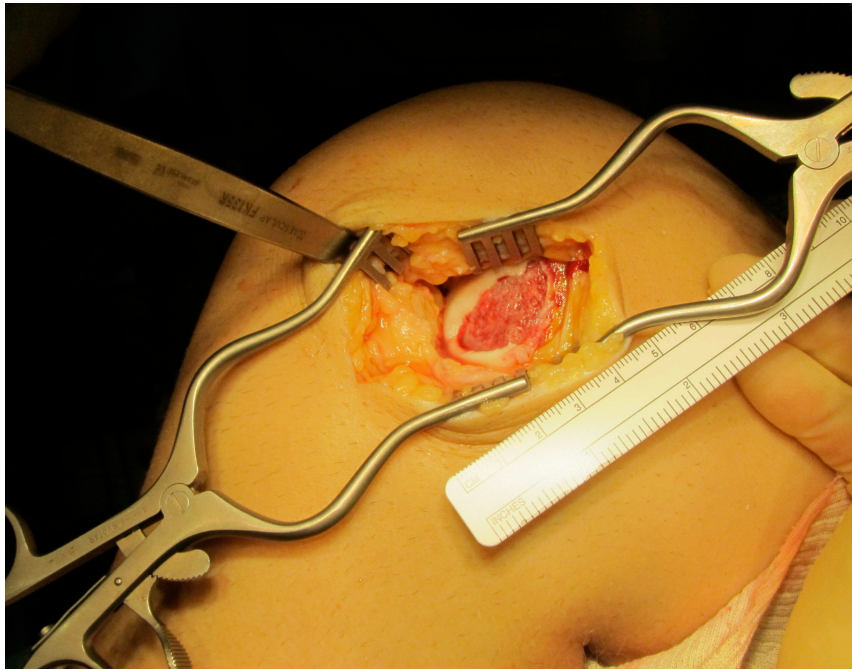


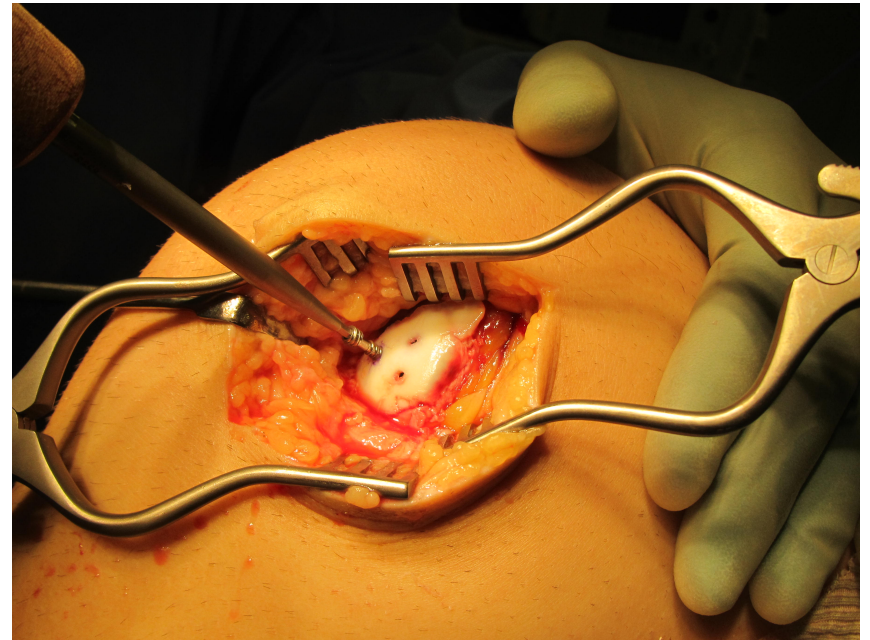
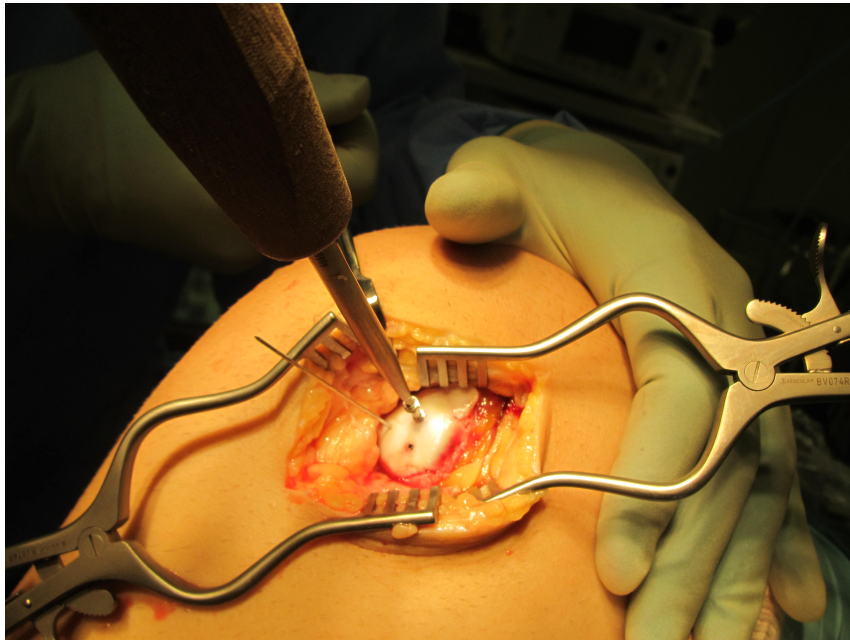
Case 3 Lateral femoral condyle

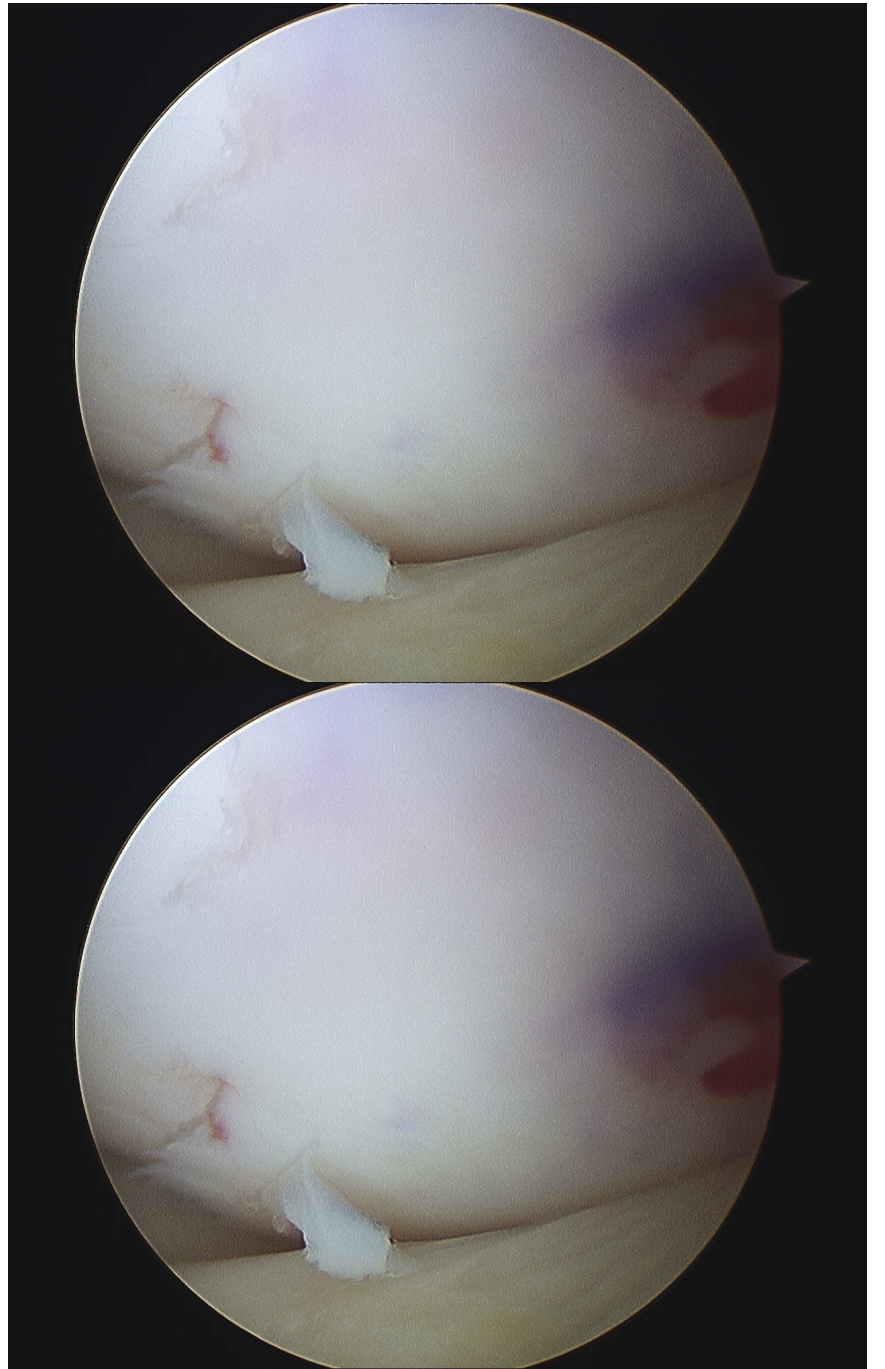
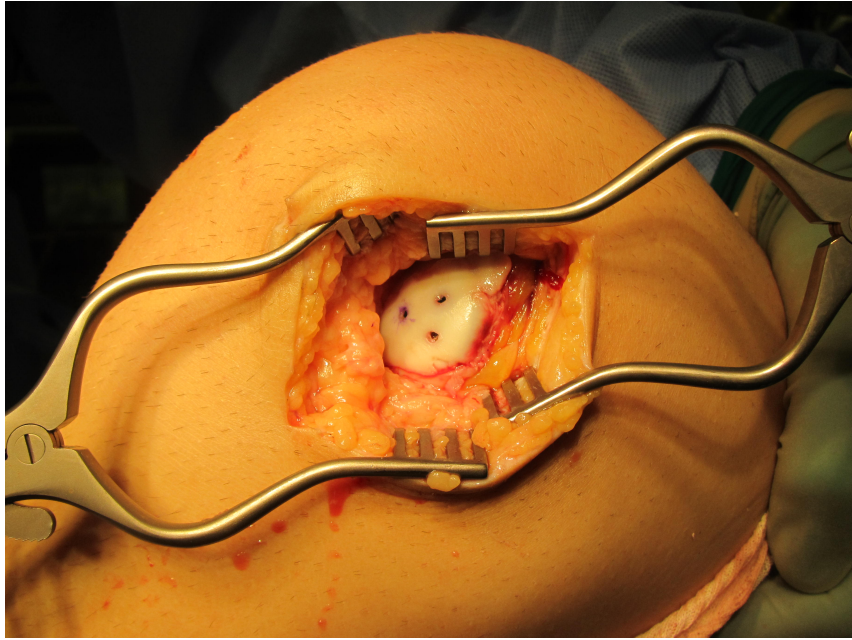




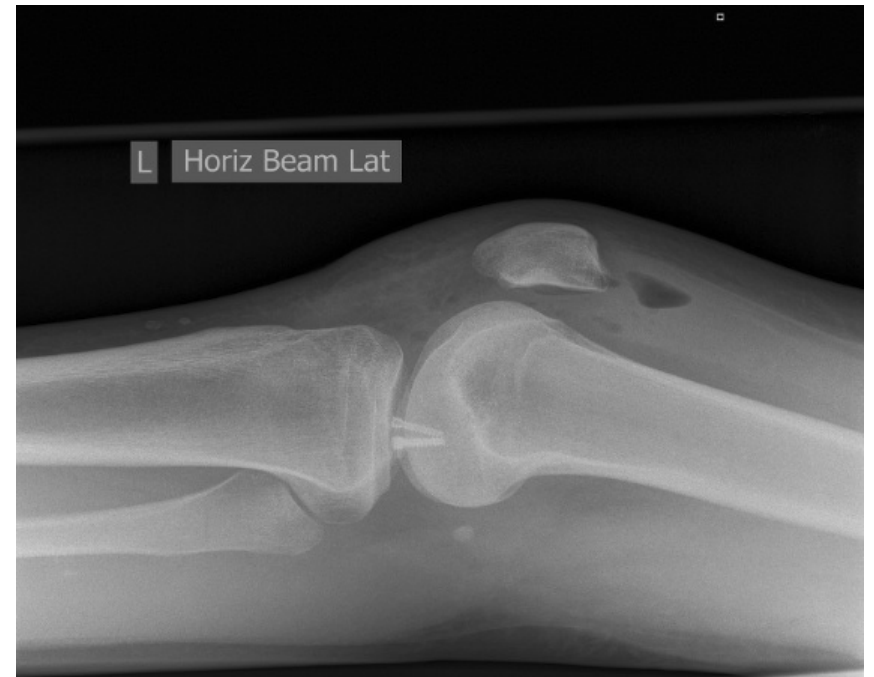
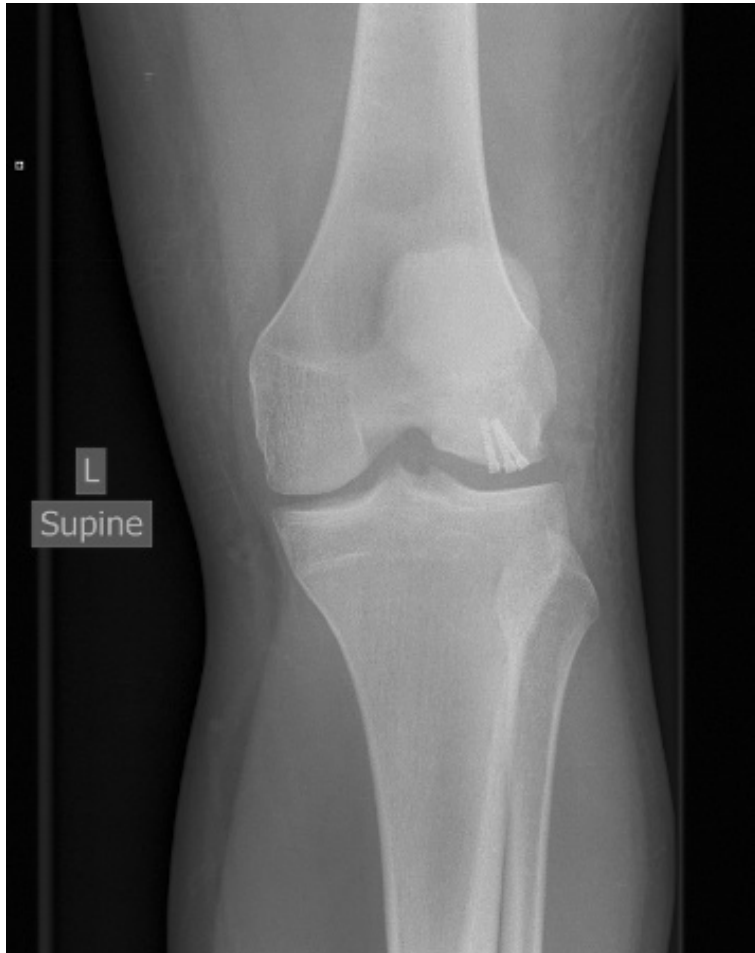




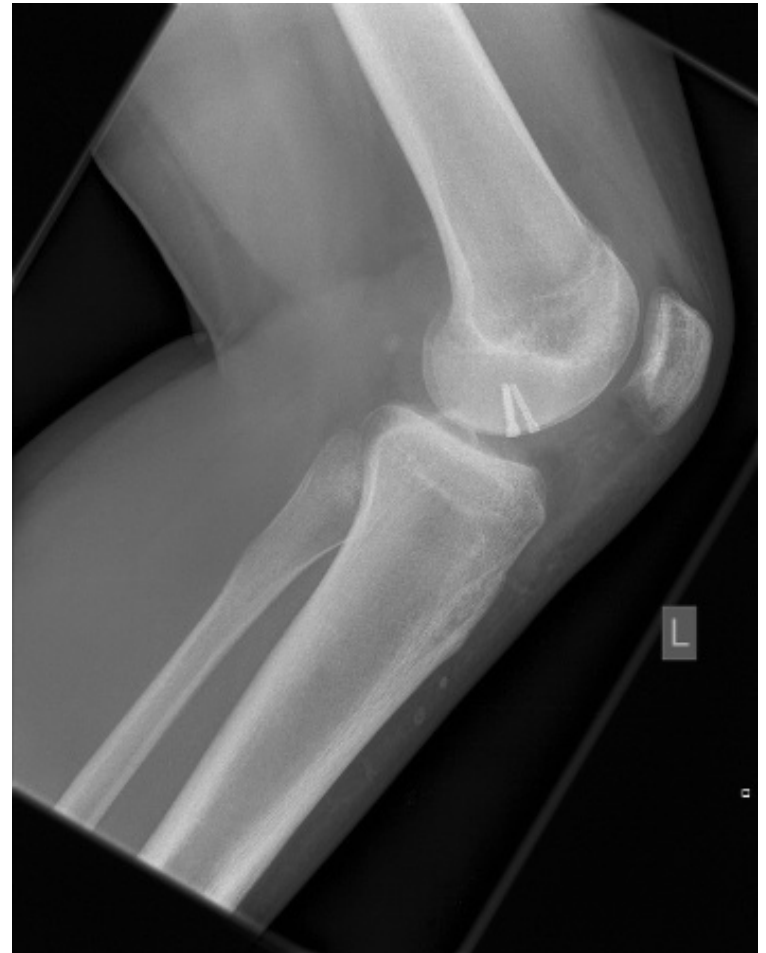
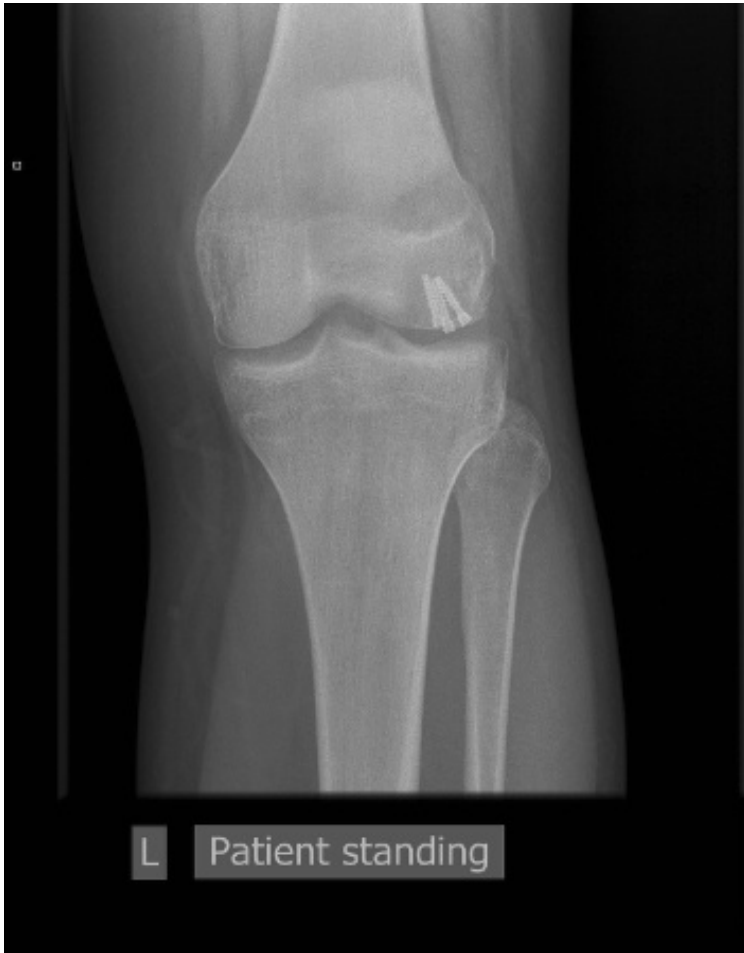
Post operative radiographs

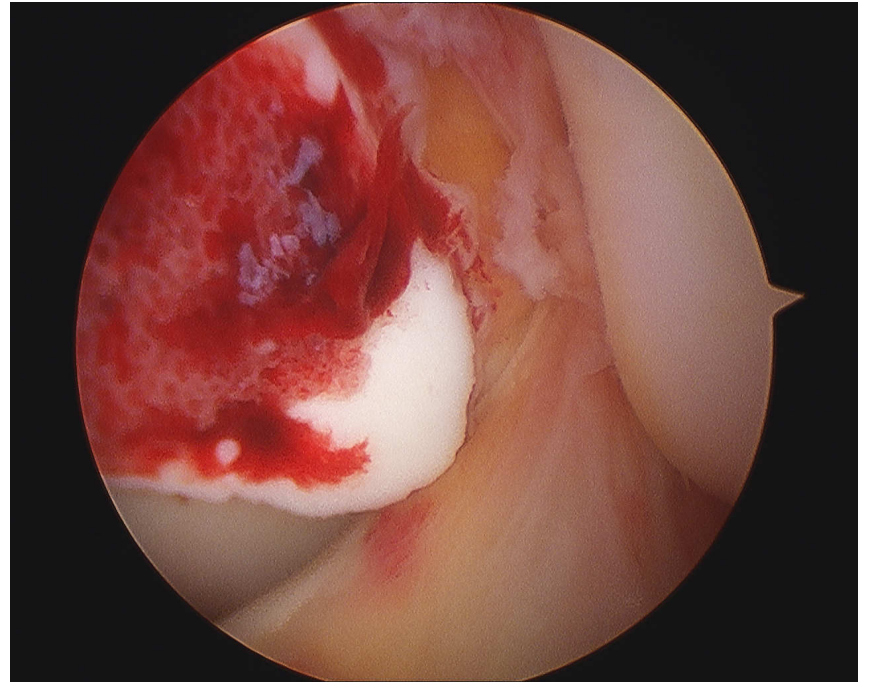
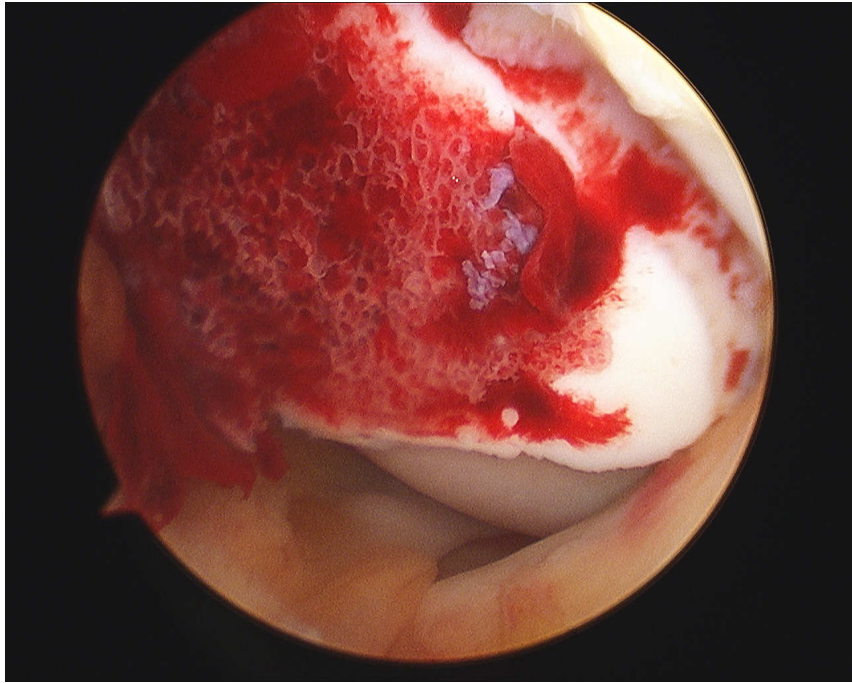


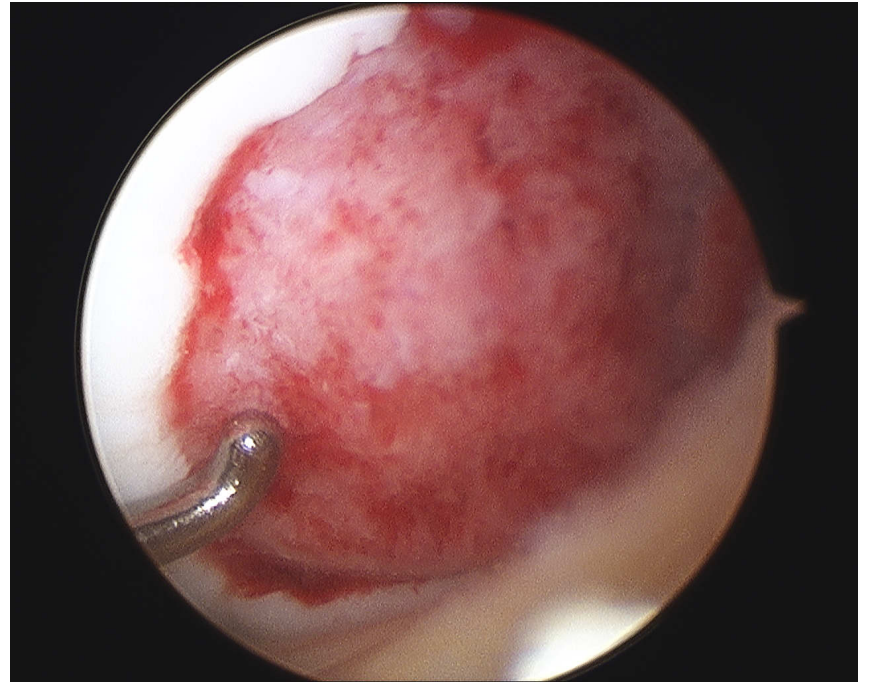
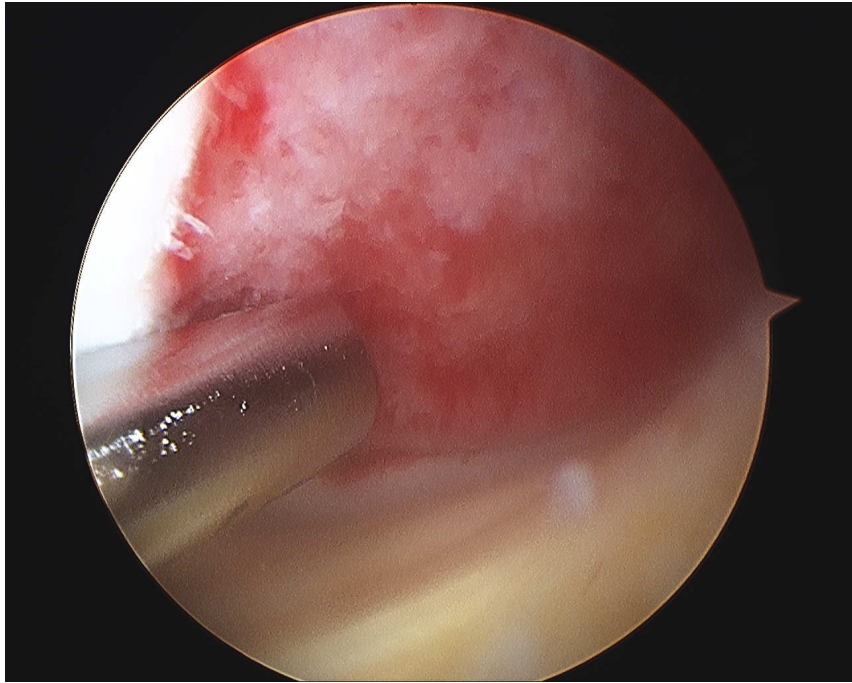
Radiographs 3 months

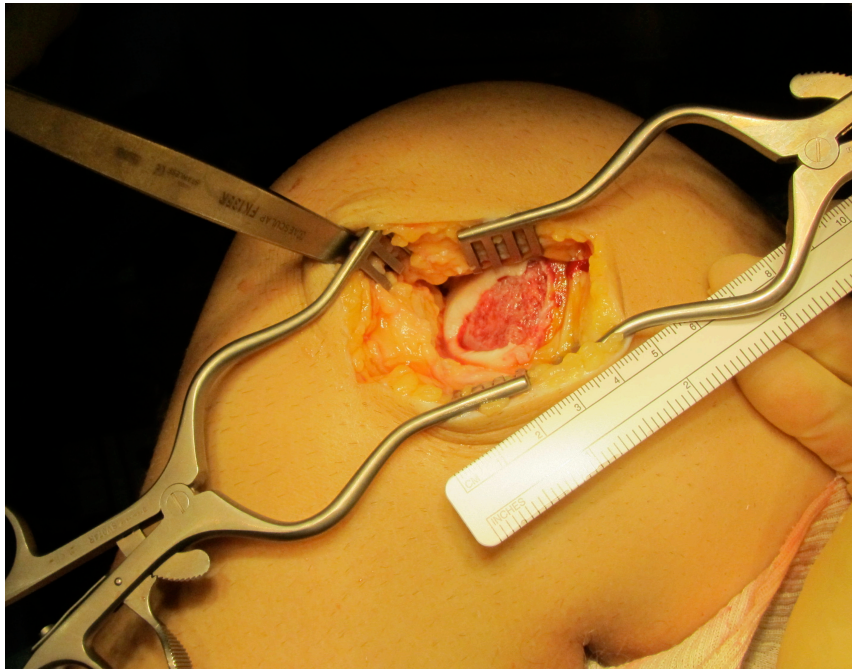


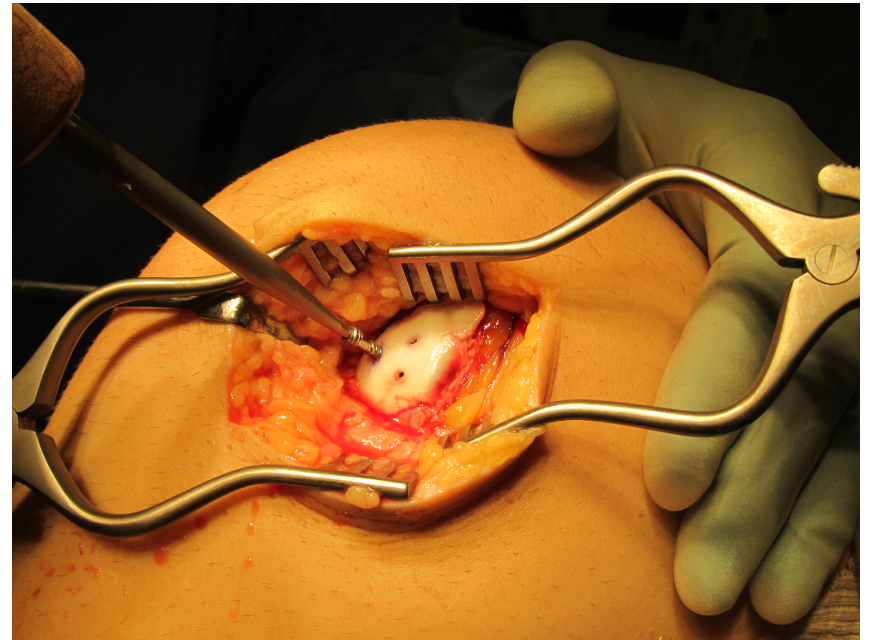
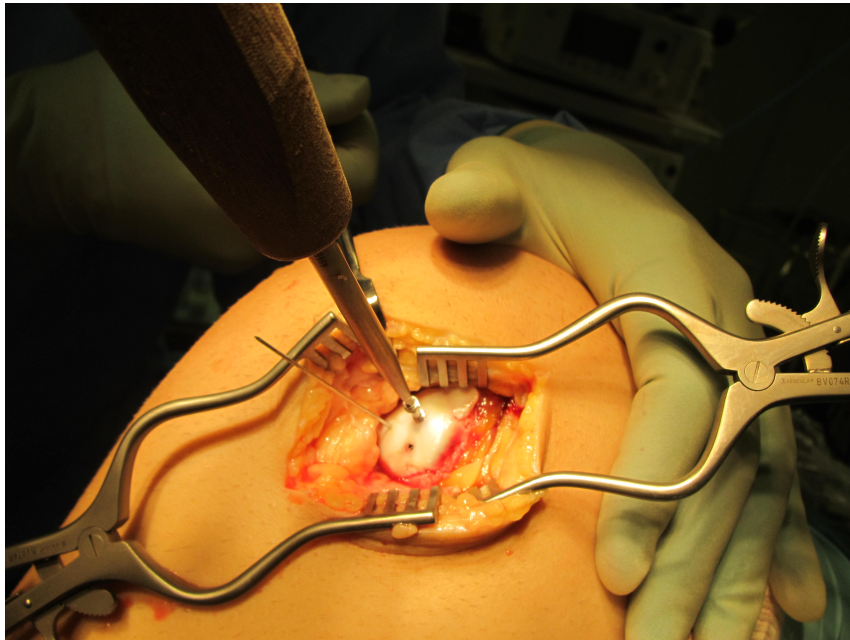
Case 4 patella dislocation

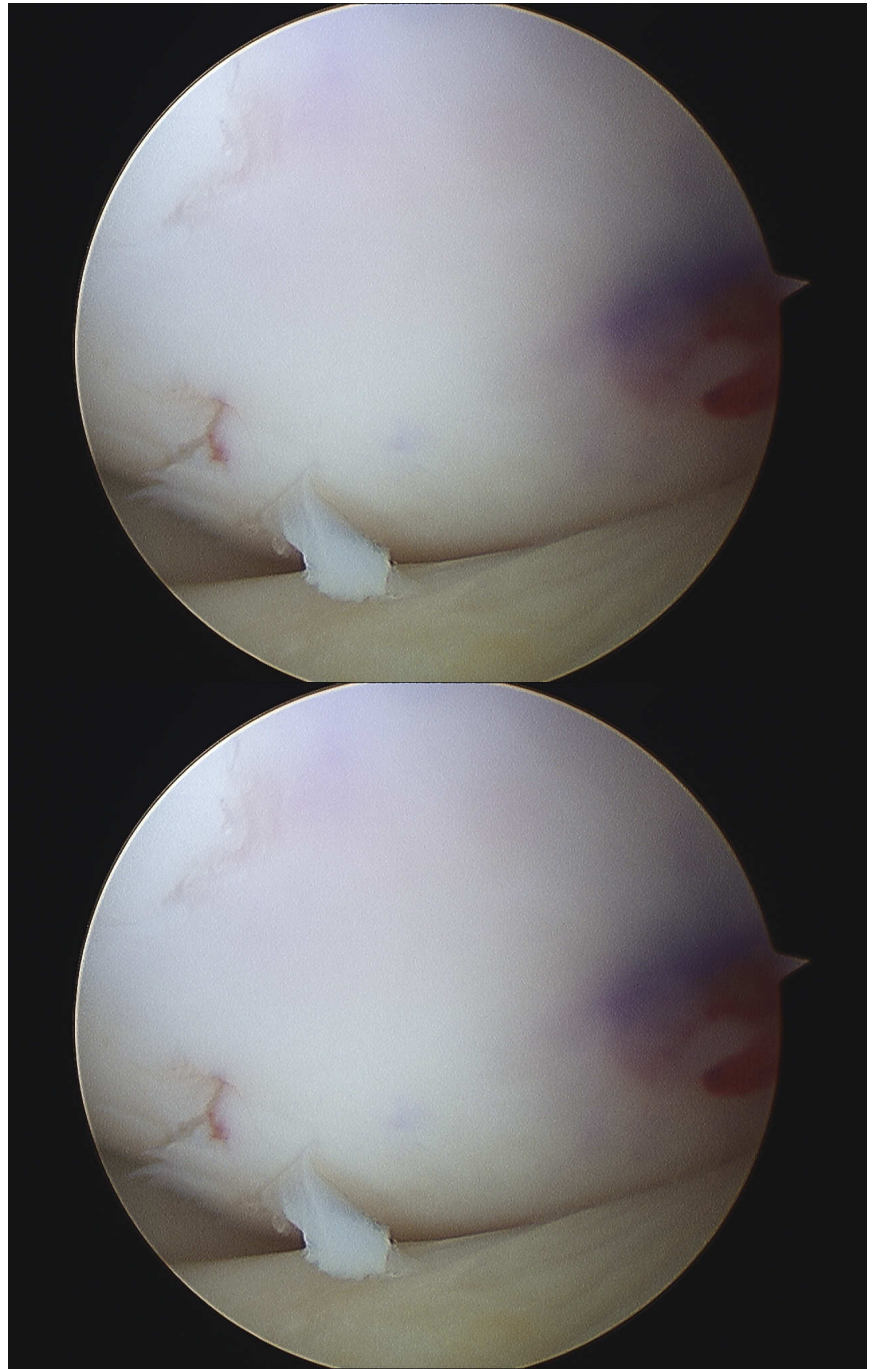
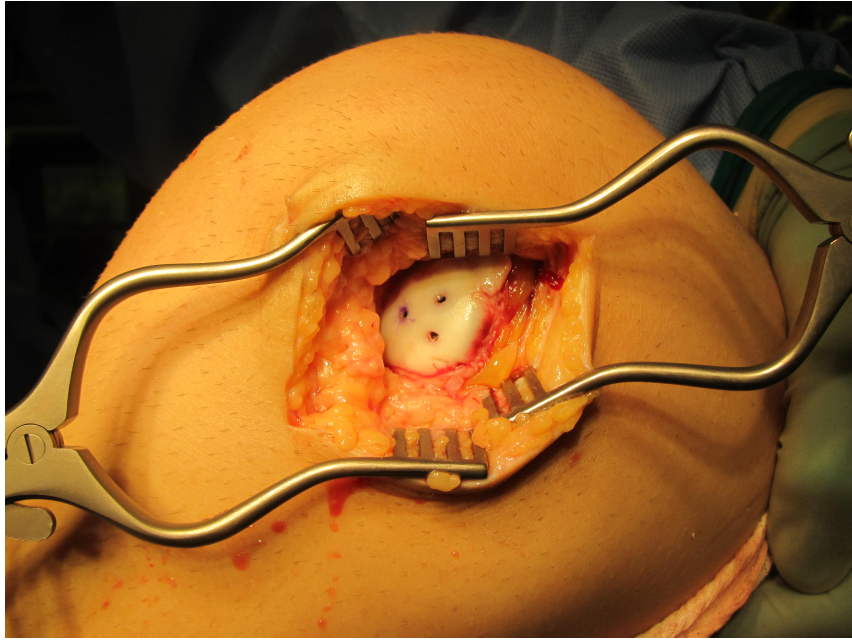












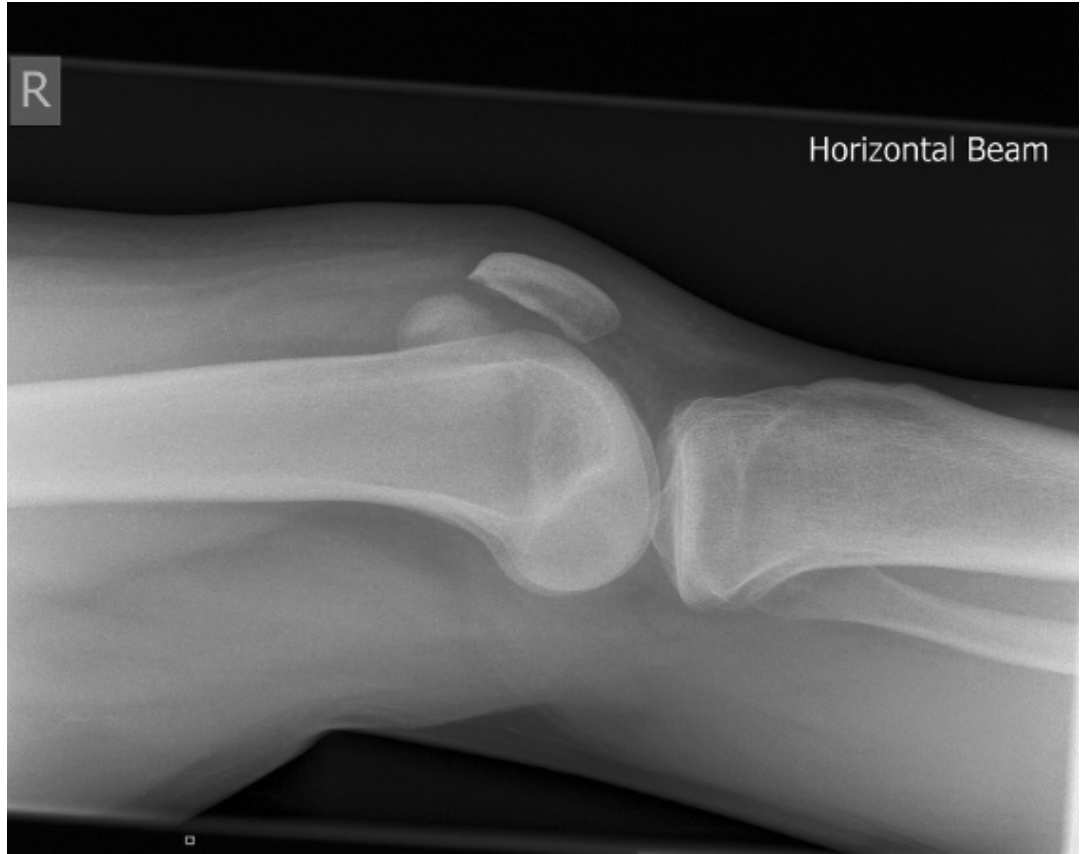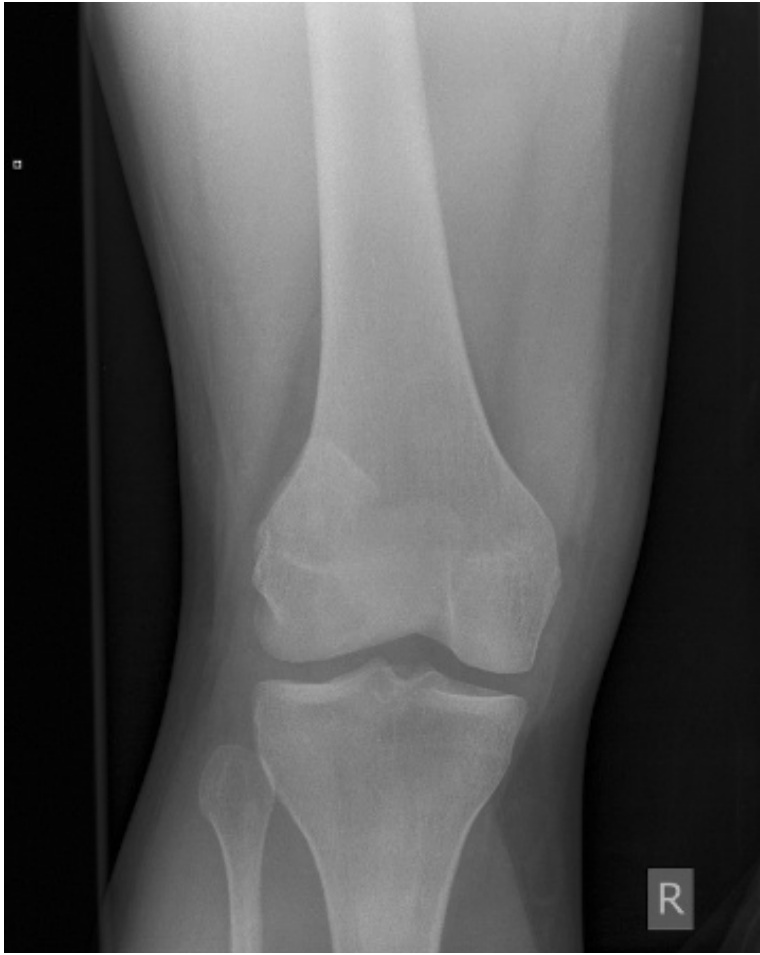Post operative radiographs

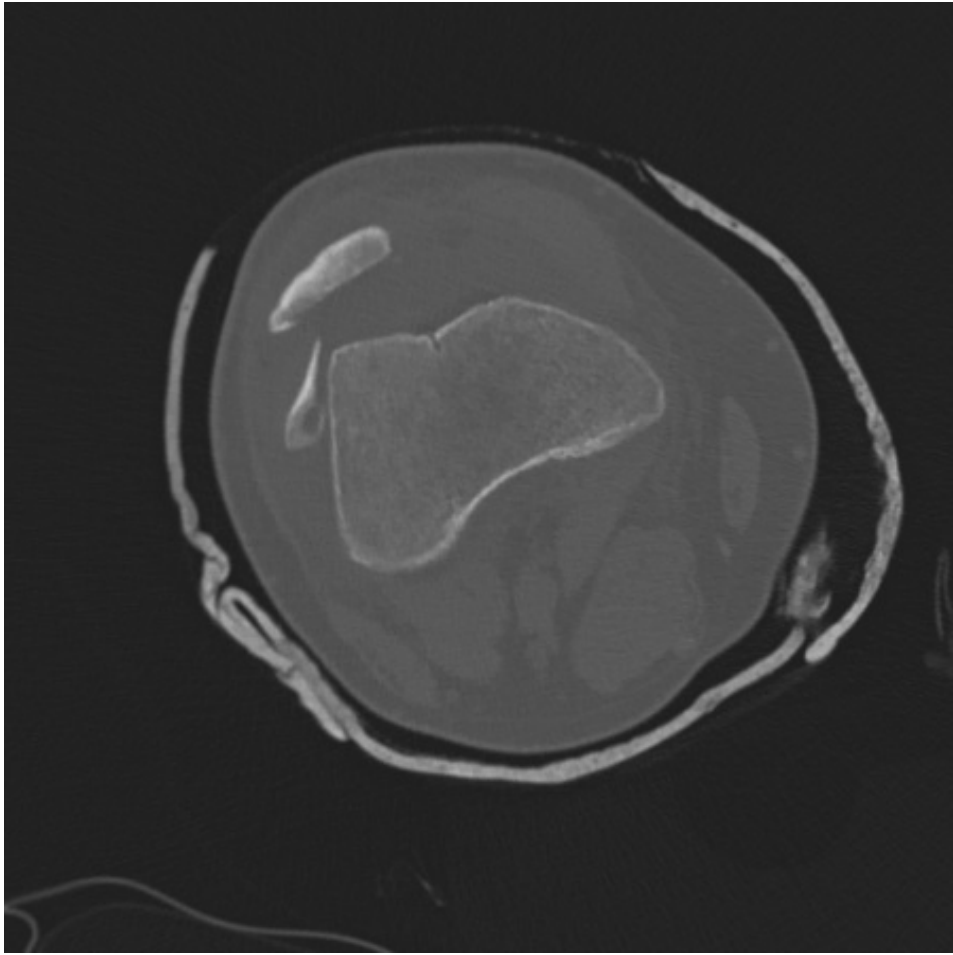


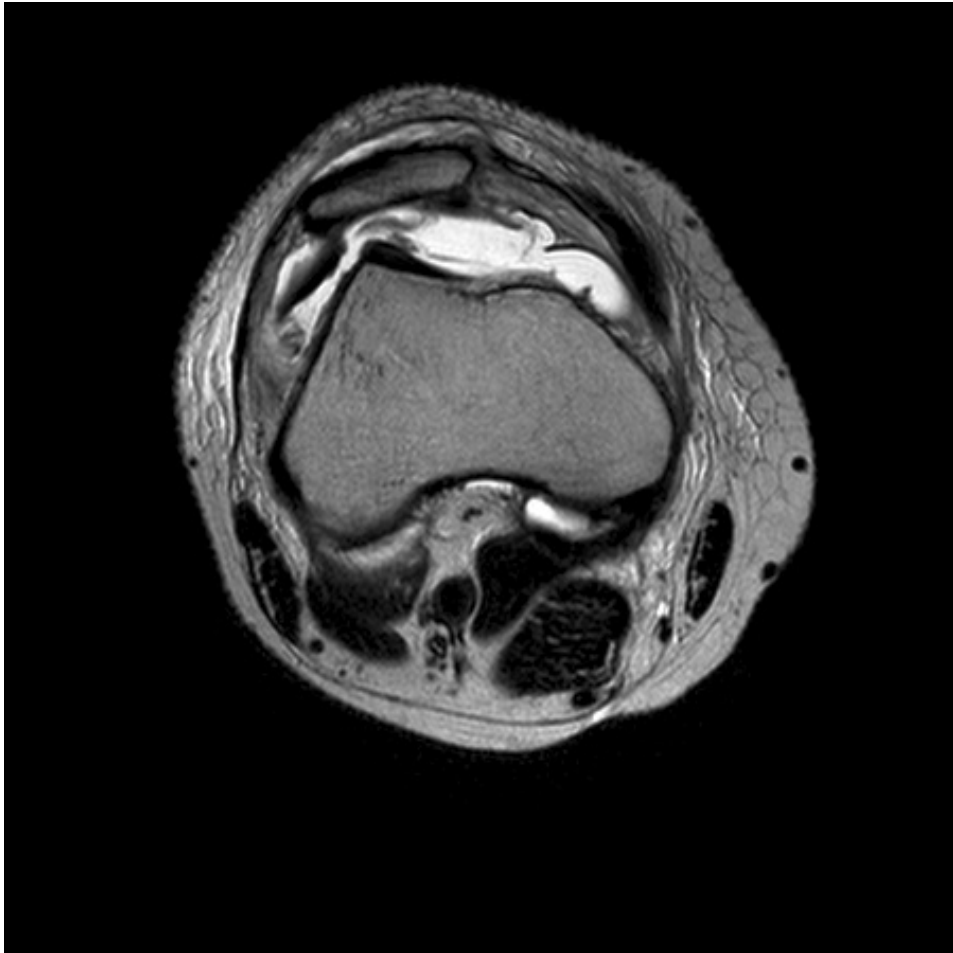Radiographs 3 months

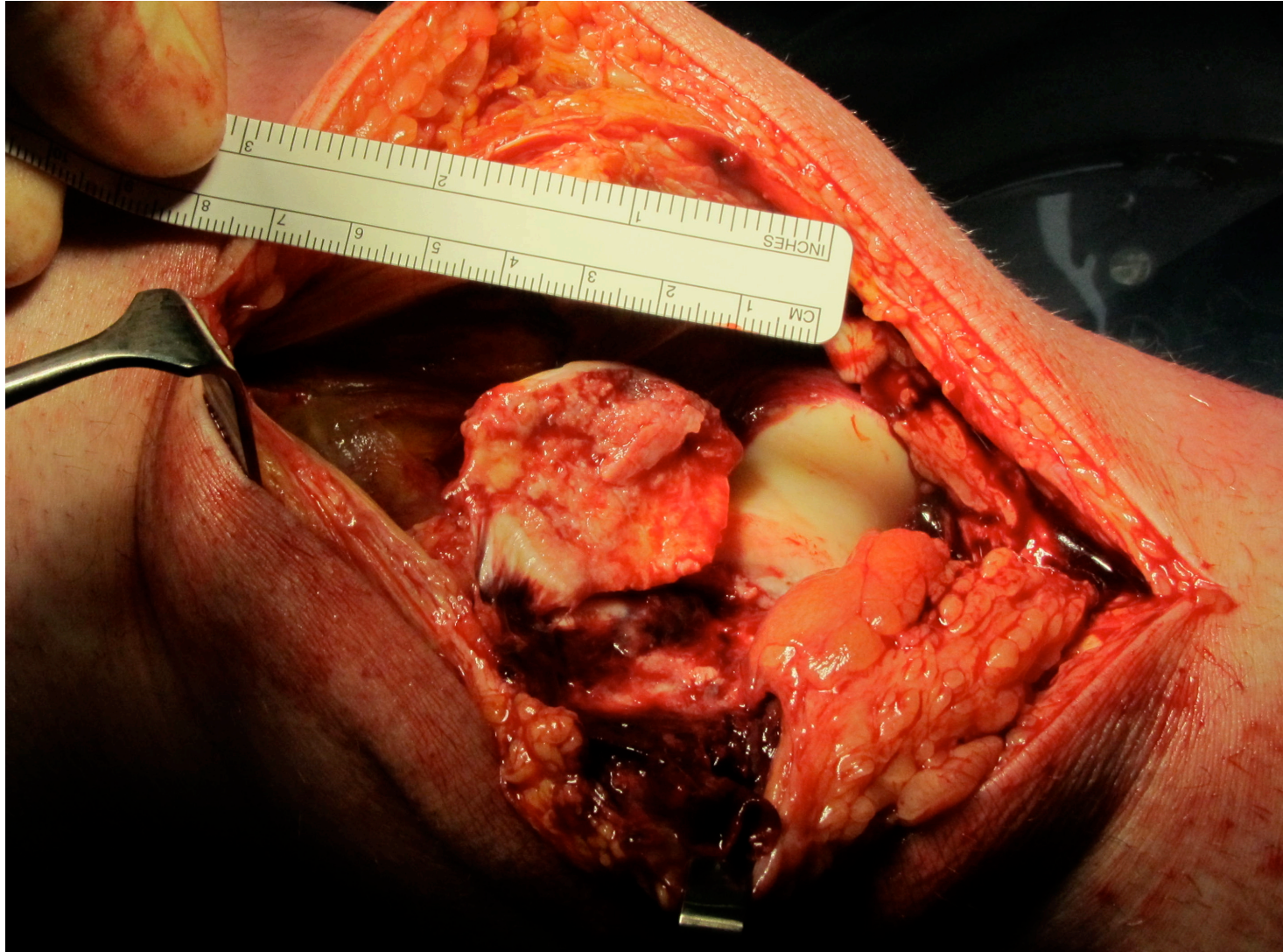


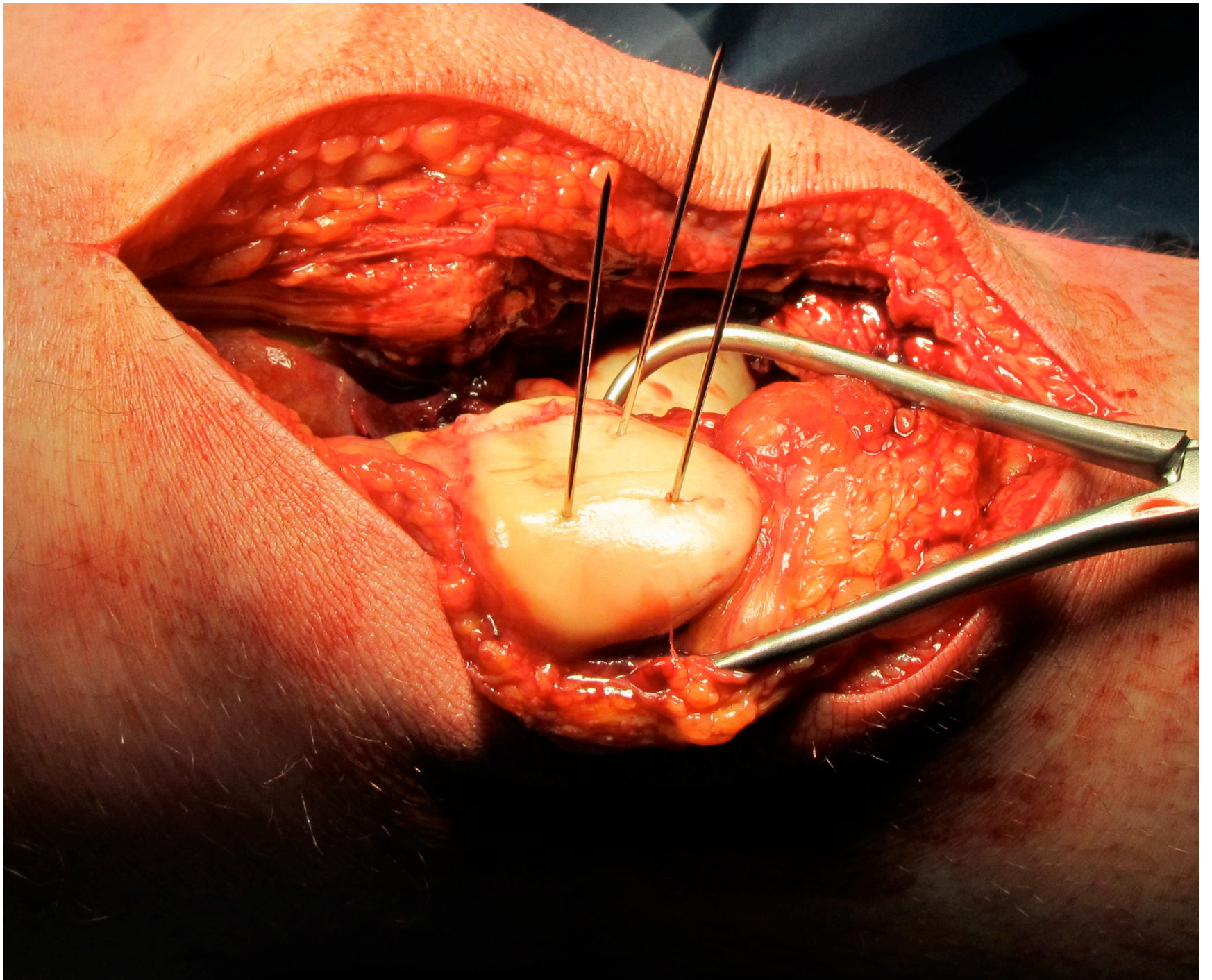
Case 5 Acute trauma patella dislocation

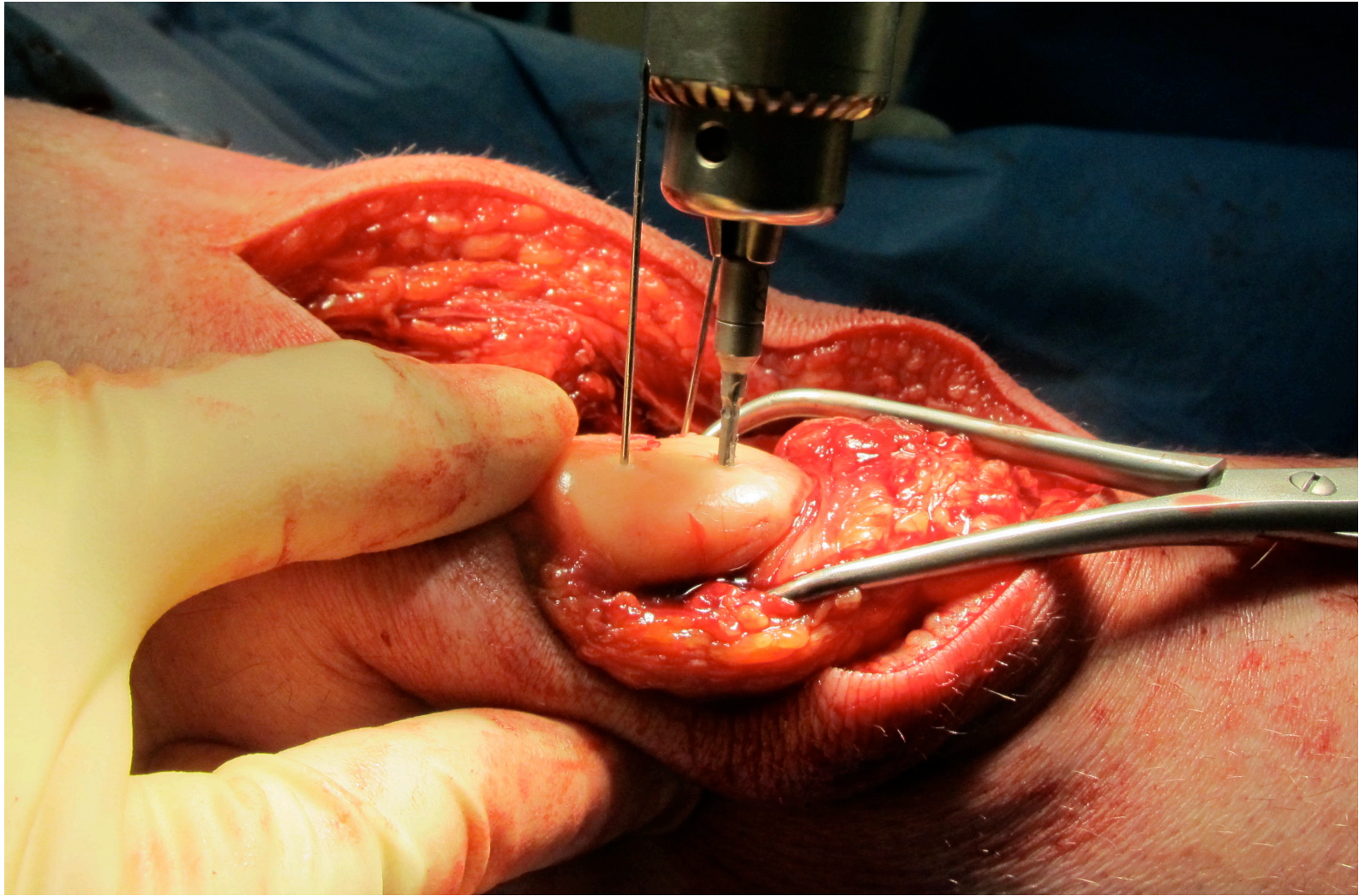


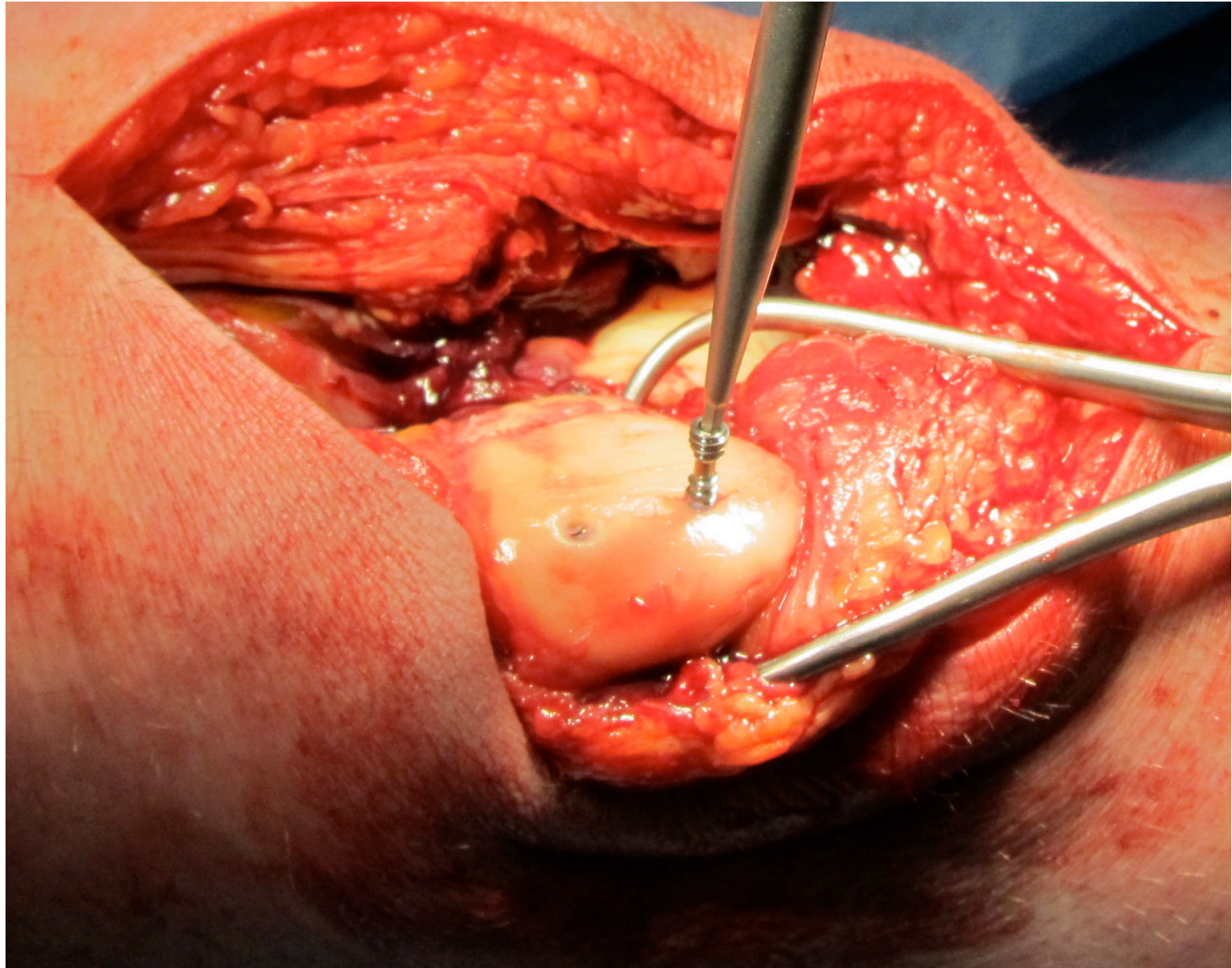


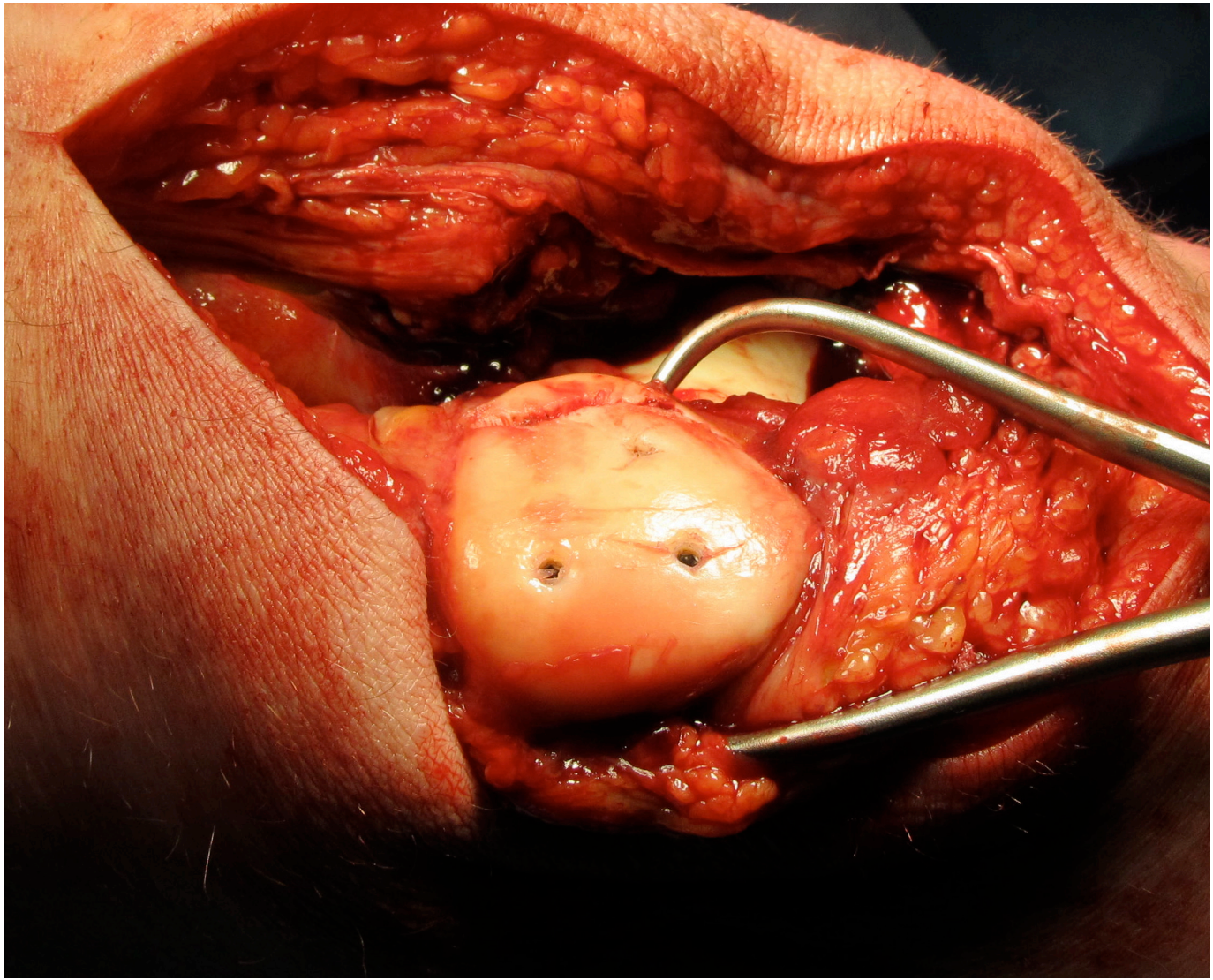


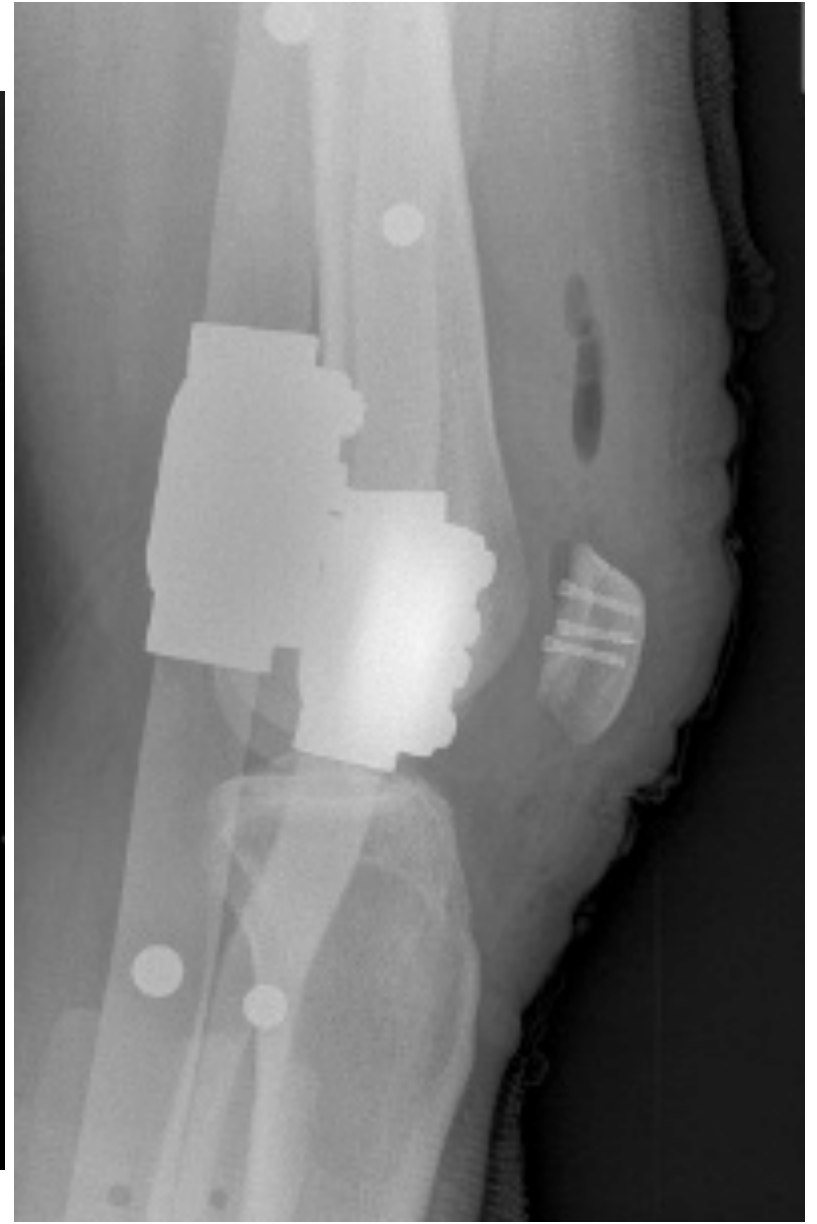
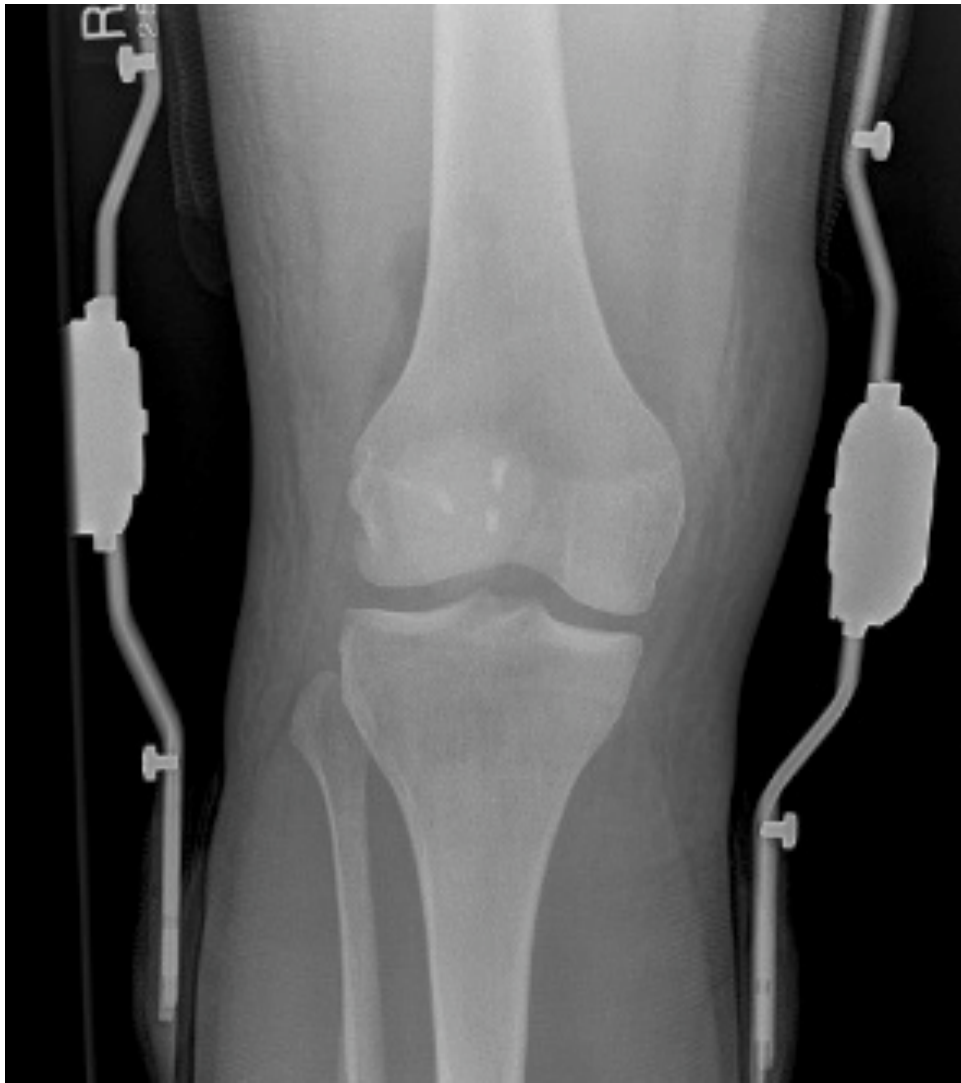

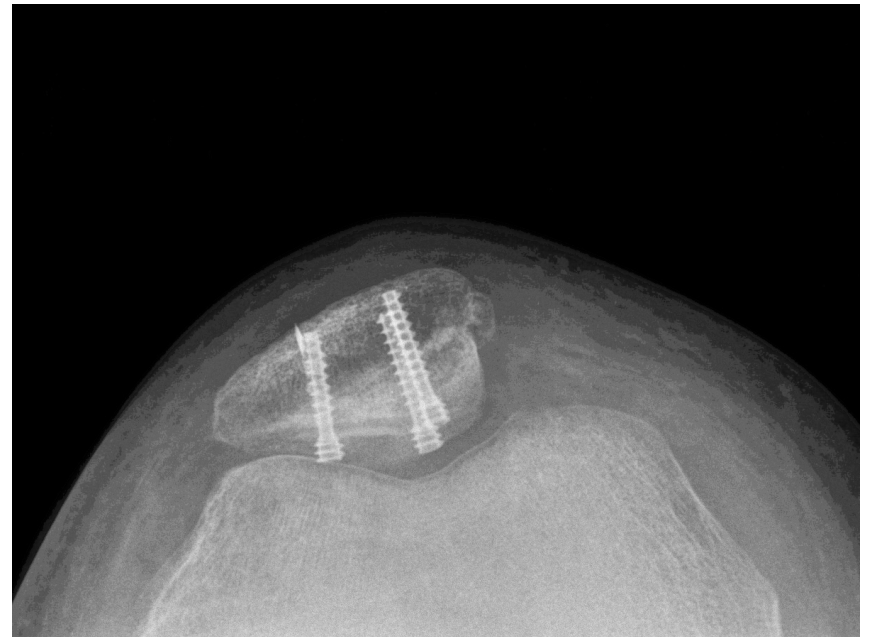

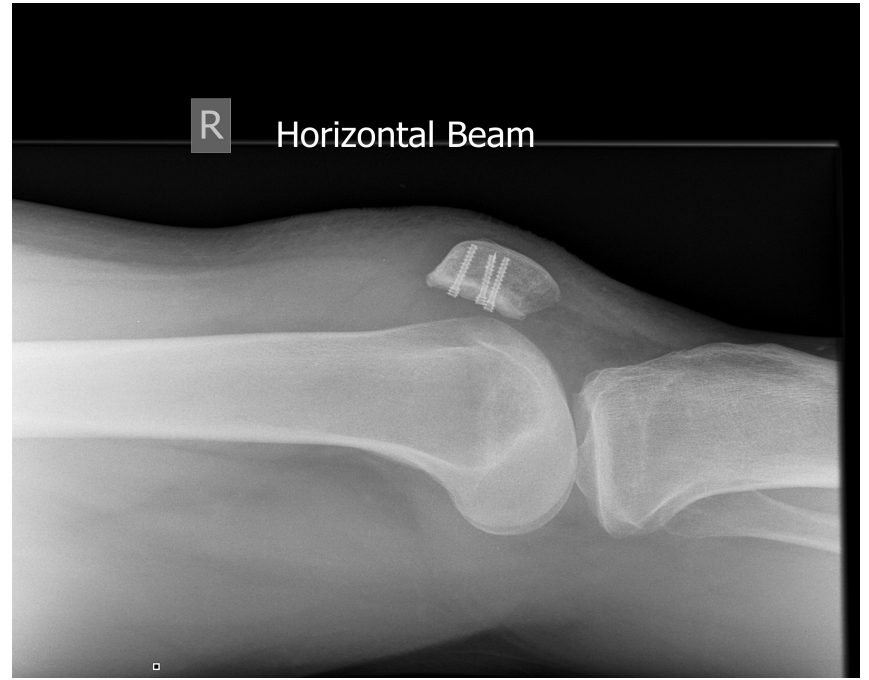
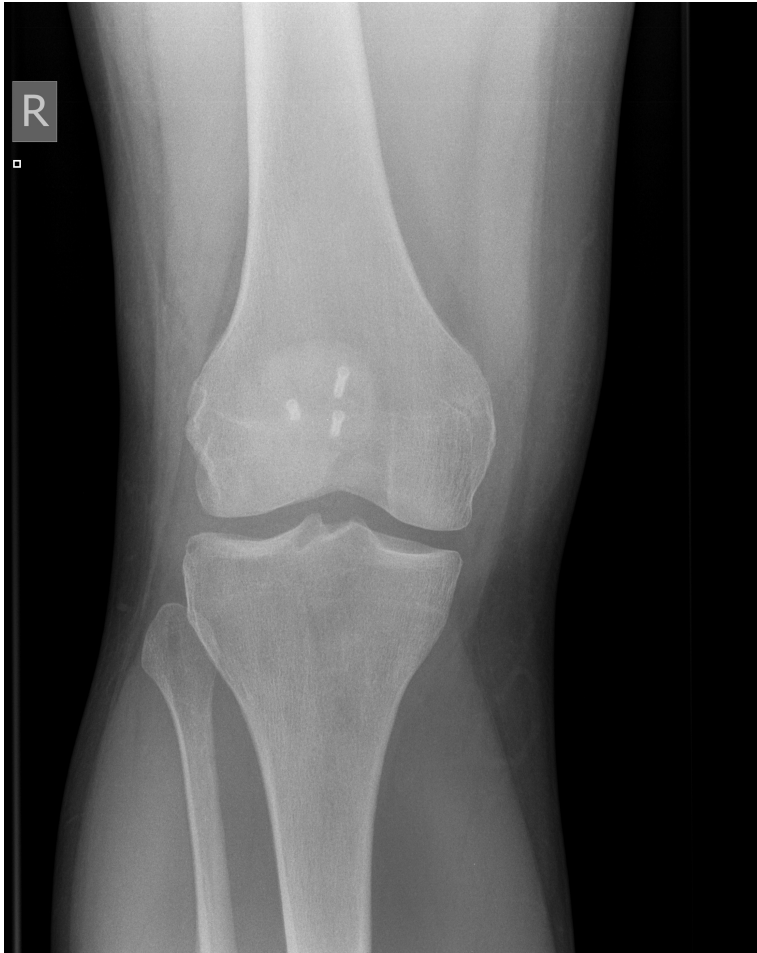









Post op rehabilitation

- Use brace 6 weeks, lockable hinge
- Tibio-femoral
 - TTWB
- Patellofemoral
 - FWB locked
- Free Range of movement exercises
 - 1-2 weeks swelling dependent
 - Cycling

Take home message-How I do it 1

- Stable > drill
- Unstable & undisplaced > drill & fix Ax
 - Differential pitch screws
- Displaced > remove & fix
 - Removal large portal
 - Preparation both surfaces
 - Differential pitch screws metal
 - Remove screws

Take home message-How I do it 2

- Displaced > remove & fix
 - Experience bio-absorbable screws not good
 - Remove screws
 - Experience trocheloplasty
 - Absorbable suture tape 5mm
 - Polydioxanone
 - Polyglycolic acid
- All early motion

18th ESSKA Congress

9 – 12 May 2018



Glasgow, Scotland, UK

www.esska-congress.org



ESSKA President
Romain Seil (Luxembourg)

Congress President
Jón Karlsson (Sweden)

Scientific Chairman
Gino M. Kerkhoffs (The Netherlands)
Fares S. Haddad (UK)
Michael T. Hirschmann (Switzerland))

Organiser & Contact
Intercongress GmbH
esska@intercongress.de



Cola



Almaty 2017 WINTER UNIVERSIADE



Fatigué mais merci de votre attention

mcarmont@hotmail.com